

Complications in Male Circumcision

MOHAMED A BAKY FAHMY



Complications in Male Circumcision



Complications in Male Circumcision

Edited by

MOHAMED A BAKY FAHMY, MD, FRCS

Professor

Pediatric Surgery

Al Azher University

Cairo, Egypt



ELSEVIER

COMPLICATIONS IN MALE CIRCUMCISION

ISBN: 978-0-323-68127-8

Copyright © 2019 Elsevier Inc. All rights reserved.

No part of this publication may be reproduced or transmitted in any form or by any means, electronic or mechanical, including photocopying, recording, or any information storage and retrieval system, without permission in writing from the publisher. Details on how to seek permission, further information about the Publisher's permissions policies and our arrangements with organizations such as the Copyright Clearance Center and the Copyright Licensing Agency, can be found at our website: www.elsevier.com/permissions.

This book and the individual contributions contained in it are protected under copyright by the Publisher (other than as may be noted herein).

Notices

Practitioners and researchers must always rely on their own experience and knowledge in evaluating and using any information, methods, compounds or experiments described herein. Because of rapid advances in the medical sciences, in particular, independent verification of diagnoses and drug dosages should be made. To the fullest extent of the law, no responsibility is assumed by Elsevier, authors, editors or contributors for any injury and/or damage to persons or property as a matter of products liability, negligence or otherwise, or from any use or operation of any methods, products, instructions, or ideas contained in the material herein.

Publisher: Cathleen Sether

Acquisition Editor: Belinda Kuhn

Editorial Project Manager: Rebeka Henry

Production Project Manager: Sreejith Viswanathan

Cover Designer: Christian Bilbow

3251 Riverport Lane
St. Louis, Missouri 63043



List of Contributors

Ahmad R. Abdel-Aal, MS

Role of Hyperbaric Oxygen Therapy in MC
Complications
Surgery Department
Assuit University
Assuit, Egypt

Jonathan A. Allan, PhD

Canada Research Chair in Queer Theory
Faculty of Arts
Brandon University
Brandon, Manitoba, Canada

**Anthony Emmanuel, BSc (Hons), DipRD, MD
(Res), MRCS (Eng)**

Urology Registrar
Solihull Hospital
Solihull, United Kingdom

Mohamed A Baky Fahmy, MD, FRCS

Professor
Pediatric Surgery
Al Azher University
Cairo, Egypt

Atieno Kili K'Odhiambo, PhD

Senior Lecturer
Department of Educational Foundations
University of Nairobi
Nairobi, Kenya

Nick Watkin, MA, MChir, FRCS (Urol)

Consultant Urologist and Professor in Urology
St George's University Hospitals
London, United Kingdom

Preface

Circumcision remains as one of the most controversial topics in current medical practice. The most important argument against circumcision is the permanent change of anatomy, histology and function of the penis, with potential complications, which were reported to be low in developed countries, whereas the rate of complication may be up to 45% when circumcision is carried out by traditional circumcisers rather than by medically trained professionals in developing countries. In some studies reporting the complications of circumcision, primary haemorrhage was the most common (52%) complication, whereas infection, meatal stenosis, incomplete circumcision, penile oedema, glanular injury, penile adhesions, iatrogenic hypospadias and urethral injuries were also detected at different rates.

There are minor complications after circumcision that cannot be avoided even when the procedure is undertaken by specialized paediatric surgeons or urologists in properly equipped centres, especially if the child or his penis is congenitally abnormal, for example, circumcising a child with excessive suprapubic fat or a child with webbed penis or microphallus.

After practicing circumcision and managing other surgeons complications in thousands of boys for

35 years in a country like Egypt (with about 90% circumcision rate), I found parents had a great urge to do this surgery even for a handicapped or critically ill child, with a possibility for higher rate of complications. So the best way to minimize complications of male circumcision (MC) and to compete against its serious effects on male health is to standardize the MC procedure and to educate both families and physicians about the potential complications and how they could manage it early and promptly.

The spectrum of post-MC complications is so wide to be discussed, so we will just focus on both the common and the uncommon complications that usually raise a debate about their management. There are different ways to classify MC complications: early or late, minor or major, local or systemic and rare or common.

PHOTO CREDITS

I'm so grateful to all my colleagues who allowed me to use some of their photos and to the parents who consented me to use the photos of their children for demonstration.

This page intentionally left blank

Abbreviations and Acronyms

AAP	American Academy of Pediatrics	HIV	Human immunodeficiency virus
AIDS	Acquired immunodeficiency syndrome	HPV	Human papilloma virus
ALAT	Alanine aminotransferase	MC	Male circumcision
BXO	Balanitis xerotica obliterans	NIS	Nationwide Inpatient Sample
CDC	Centers for Disease Control and Prevention	STI	Sexually transmitted infection
CI	Confidence interval	UNAIDS	Joint United Nations Programme on HIV/AIDS
EMLA	Eutectic Mixture of Local Anaesthetics	VMMC	Voluntary medical male circumcision
HBO	Hyperbaric oxygen	WHO	World Health Organization
HBV	Hepatitis B virus		
HCV	Hepatitis C virus		

Contents

- 1 Introduction, 1**
Mohamed A Baky Fahmy, MD, FRCS
 - 2 Male Circumcision: Historical and Religious Background, 11**
Atieno Kili K'Odhiambo, PhD
 - 3 Benefits of Male Circumcision (Circumcision Apparition), 17**
Mohamed A Baky Fahmy, MD, FRCS
 - 4 Circumcision and Penile Cancer, 21**
Anthony Emmanuel, BSc (Hons), DipRD, MD (Res), MRCS (Eng) and Nick Watkin, MA, MChir, FRCS (Urol)
 - 5 Methods and Techniques of Circumcision, 25**
Mohamed A Baky Fahmy, MD, FRCS
 - 6 Anaesthesia and Analgesia for Male Circumcision and Its Complications, 39**
Mohamed A Baky Fahmy, MD, FRCS
 - 7 Prevalence of Male Circumcision Complications, 49**
Mohamed A Baky Fahmy, MD, FRCS
 - 8 Bleeding Complications, 65**
Mohamed A Baky Fahmy, MD, FRCS
 - 9 Infectious Complications of Circumcision, 73**
Mohamed A Baky Fahmy, MD, FRCS
 - 10 Nonaesthetic Circumcision Scarring, 99**
Mohamed A Baky Fahmy, MD, FRCS
 - 11 Circumcision Scars and Aesthetic Concerns, 135**
Jonathan A. Allan, PhD
 - 12 Post-Male Circumcision Penile Injuries, 145**
Mohamed A Baky Fahmy, MD, FRCS
 - 13 Role of Hyperbaric Oxygen Therapy in Male Circumcision Complications, 171**
Ahmad R. Abdel-Aal, MS and Mohamed A Baky Fahmy, MD, FRCS
 - 14 Prevention of Male Circumcision Complications, 177**
Mohamed A Baky Fahmy, MD, FRCS
 - 15 Reconstructive Surgery for Circumcision Complications, 179**
Mohamed A Baky Fahmy, MD, FRCS
- INDEX, 189**

Nonaesthetic Circumcision Scarring

MOHAMED A BAKY FAHMY, MD, FRCS

ABSTRACT

Circumcision may be undertaken as a body modification of the genitals to change the look of the penis to appeal more to certain aesthetics, but sometimes it may leave a permanent change of the natal characteristics of a body part, which will ever be subject to dispute, particularly from the cosmetic point of view. Many complications may result after nonaesthetic preputial cutting or the unhealthy healing of the circumcision wound. These complications usually manifest late, weeks or months after the procedure, and result in early family dissatisfaction and later on have a psychic impact on a man's satisfaction with his penis and may lead to loss of self-esteem.

KEYWORDS

Incomplete circumcision; Keloid and hypertrophic scar; Paraphimosis; Penile adhesions; Phimosis; Post-circumcision lymphoedema; Post-MC concealed penis; Post-MC smegma collections; Residual prepuce; Skin bridge; Sutures marks; Untidy circumcision.

Circumcision may be undertaken as a body modification of the genitals to change the look of the penis to appeal more to certain aesthetics, but sometimes it may leave a permanent change of the natal characteristics of a body part, which will ever be subject to dispute, particularly from the cosmetic point of view.

Many complications may result after nonaesthetic preputial cutting or the unhealthy healing of the circumcision wound. These complications usually manifest late, weeks or months after the procedure, and result in early family dissatisfaction and later on have a psychic impact on a man's satisfaction with his penis and may lead to loss of self-esteem.

Complications of excessive or improper tissue scarring after male circumcision (MC) have a wide spectrum of presentations, not only including aesthetic problems, but also a functional drawbacks could also result. These complications have variable incidence and are not commonly reported, and they are difficult to classify, as many categories overlap each other or occur in

sequence, for example, incomplete MC may result in cicatricial phimosis and excess inner preputial layer which may result in a keloid scar. Some complications may be termed as incomplete circumcision by some surgeons, but it is called untidy circumcision by others.

There are no definite universal criteria for the ideal circumcision scar, and also circumcision is not performed in the same manner in different communities. A 'normal' looking circumcised penis in a country may seem ugly and unacceptable by people from other parts of the world.

Generally, the circumcision line should be close to the glans as possible, limiting the width of inner prepuce up to 5–6 mm in newborns and 7–8 mm in older boys; this not only helps give an acceptable look to the penis but also prevents the so-called 'entrapped penis' by making it impossible for the circumcision line to move distal to the glans and retract proximally easily¹ (Fig. 10.1).

Post-MC aesthetic complications are mostly iatrogenic and imminent, and certain factors may be considered as leading to poor cosmesis, such as

- Impertinent tissue handling.
- Insufficient haemostasis.
- Using thick heavy sutures with long absorption time.
- Failing to recognize anatomic diversities or abnormalities.
- Excessive resection of prepuce.
- Too tight dressing.

There is no study documenting the penile appearance beyond the first year of life in the circumcised population, but it is estimated that at least 2.8% of parents will complain of the cosmetic appearance.¹

We will discuss nonaesthetic circumcision scarring complications under the following headings:

- Untidy circumcision
- Penile adhesions
- Skin bridge
- Incomplete circumcision
- Post-MC concealed penis (CP)
- Phimosis
- Paraphimosis
- Keloid and hypertrophic scar



FIG. 10.1 An aesthetic regular scar with a minimal rim of inner prepuce after sleeve circumcision.

- Suture marks
- Post-MC smegma collections
- Post-circumcision lymphoedema

UNTIDY CIRCUMCISION (UGLY CIRCUMCISION SCAR)

Circumcision is a procedure that will alter the entire anatomy and the look of the penis, which itself carries a countless variations among populations, so it is extremely difficult to standardize the shape and appearance of the penis after this operation. Different studies concluded with a diverse opinion about the aesthetic look of the penis after MC.¹

Cosmetic results were compared and rated by the Patient and Observer Scar Assessment Scale (POSAS)² as the following:

Good: Linear scar with minimal or no puckering.

Average: Linear scar with puckering of the surrounding skin without depression.

Poor: Severe puckering and depressed irregular scar.

Fig. 10.1 represents my own opinion about the desirable scar after circumcision by dissection method, with a thin circular scar around the coronal sulcus with a narrow rim of inner prepuce left, a preserved frenulum and adequate penile skin to allow, later on, the erected penis to stretch smoothly.

Irregularity of the healed wound after MC, which may result in an untidy scar, is usually due to heavy suturing, post-MC infection, haematoma formation or leaving the compression bandage for a longer time after circumcision. Such cases are different from cases of incomplete circumcision, which had a normal scar edge but excess amount of residual prepuce, and also cases of localized skin bridges.³

Excessive scarring at the circumcision edge may be due to uneven incision lines, which usually occur in guillotine method and free-handed sleeve circumcision by inexperienced surgeons. Such cases may deserve correction and proper reconstruction under general anaesthesia by a reconstructive surgeon with a good experience in penile surgery, as any attempt to repair such cases early by an inexperienced surgeon may result

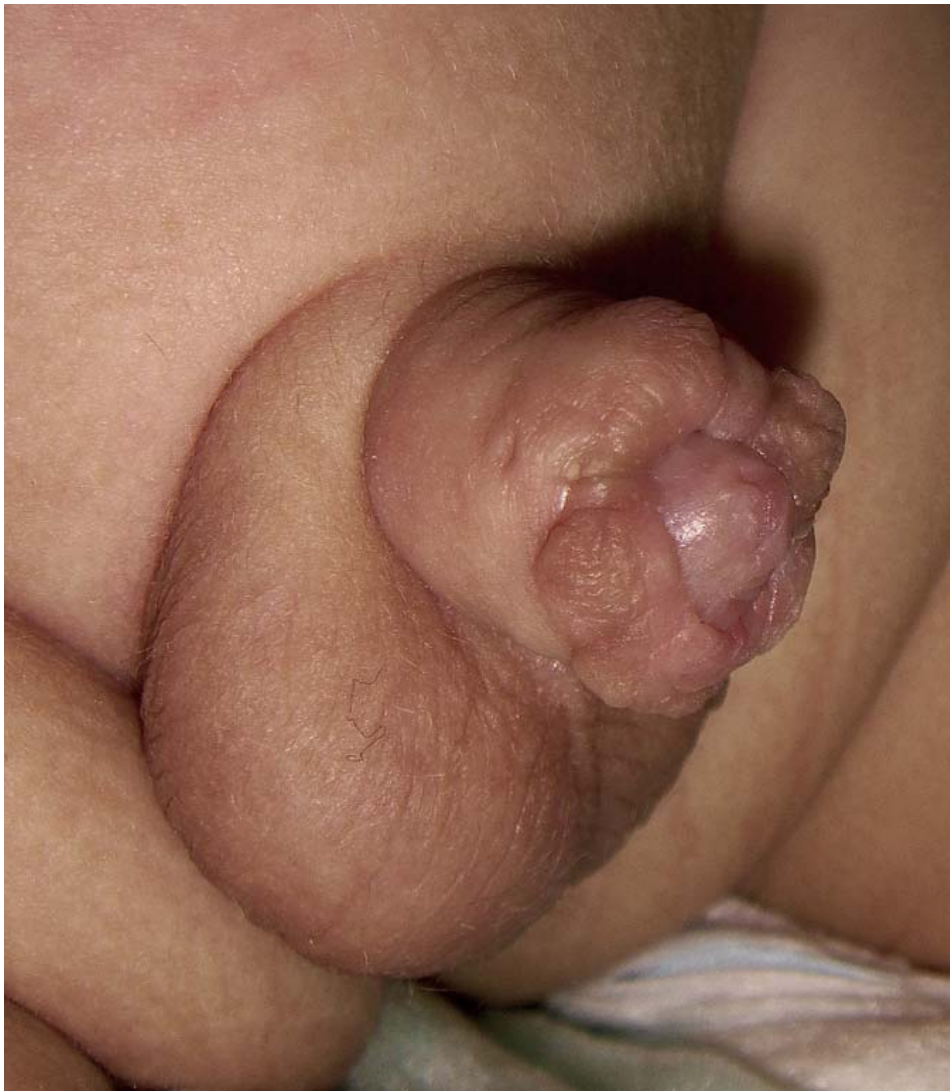

FIG. 10.2 Irregular post-male circumcision wavy scar covering the sulcus and part of the glans.

in more skin loss, penile concealment and deformities (Fig. 10.2).

Unequally inner or outer preputial cutting may result in excess skin or mucous membrane in one side of the healed scar. This may be encountered in either free-handed or guillotine method, but uncommon with the use of the Gomco and Plastibell methods (Figs. 10.3 and 10.4).

Bad mucosal healing, irregular circumcision scar and suture sinus tracts result collectively in a bad cosmesis of the scarring around the corneal sulcus (Fig. 10.5).

Glans injury or cauterization by diathermy during MC, or a post-circumcision infection, may result in isolated scarring and disfigurement of the glans penis, and such cases are extremely difficult to repair (Fig. 10.6).

The whole concept of an aesthetic prepuce will be discussed in Chapter 11.

PENILE ADHESIONS

Penile adhesion is a broad term for different pathologic condition. The most common one is the localized form of skin bridge. Penile adhesions are a relatively common complication of circumcision, especially at neonatal age, and are the primary reasons for reoperation in the late postoperative period.

Predisposing Factors

Adhesions are more likely in children with an increased weight for length percentile, in children with a large suprapubic fat pad with abnormal dartos attachments to the skin and in cases of pre-existing penoscrotal webbing or ventral penile skin deficiency. Adhesions are also common in neonatal MC, as the inner prepuce

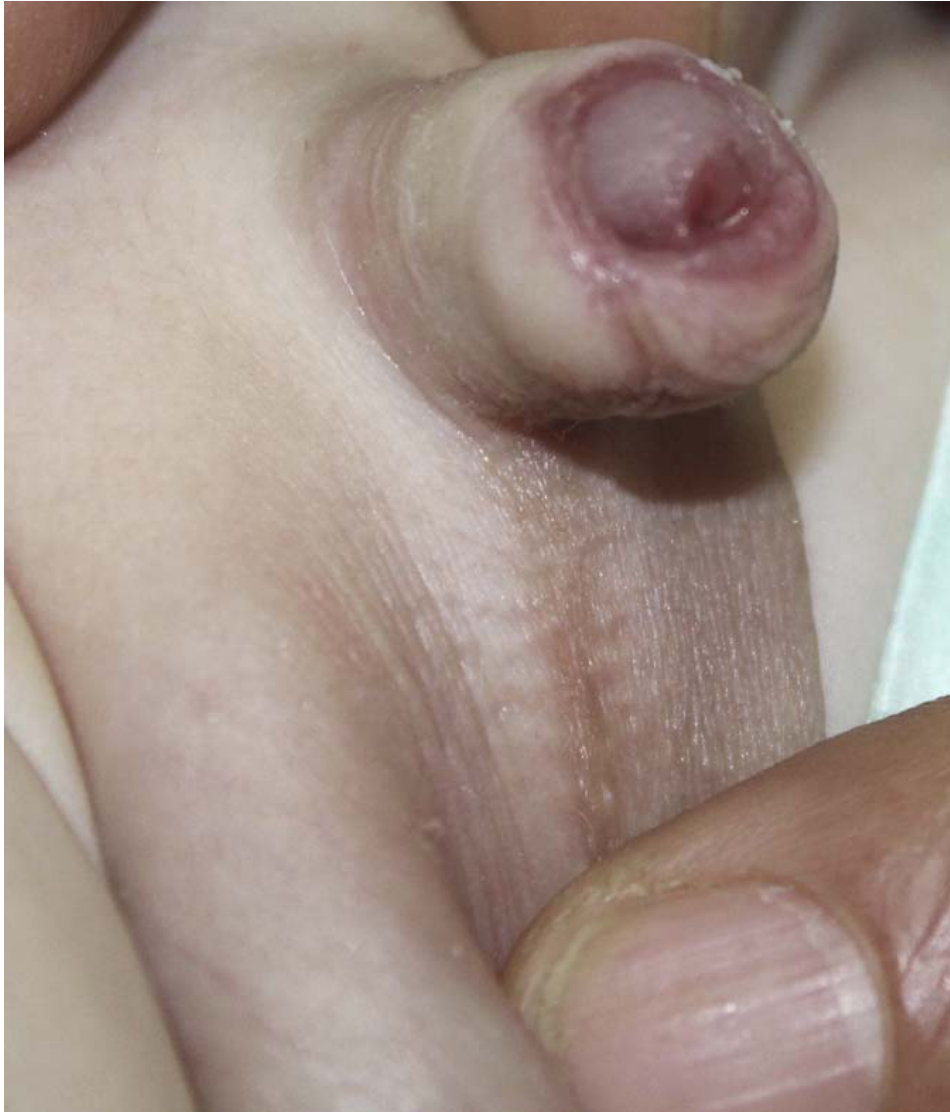

FIG. 10.3 Unequal scar with excess outer and inner preputial layers at the left side.

is physiologically adherent to the glans, and any forcible attempt to separate it will result in a denuded glandular surface, which will easily heal with fibrous scarring with the surrounding penile skin. Different forms of penile adhesions may follow post-MC infectious complications, especially bacterial balanitis; also, balanitis xerotica obliterans (BXO) cases after MC may be associated or complicated with severe penile adhesions, especially if the circumcision wound is untidy (Fig. 10.7).

Adhesions could be seen at different levels and between different parts of the penis:

- Adhesions between excess remnants of mucous membrane (inner preputial layer) and the glans penis, which may be partial or complete forming a ring around the glans (Fig. 10.8).
- Complete adhesions of the redundant cut edges of the prepuce with the raw surface of the glans, which may eventually lead to cicatricial phimosis (Fig. 10.9).
- Adhesions between a localized raw surface of the glans and penile skin forming different forms of skin bridging between the penile shaft and the glans penis, crossing the coronal sulcus (Fig. 10.10).

All these adhesions of the mucosal collar to the glans are avoidable by gentle preputial retraction, meticulous tissue handling and use of barrier ointments in the early post-operative period.

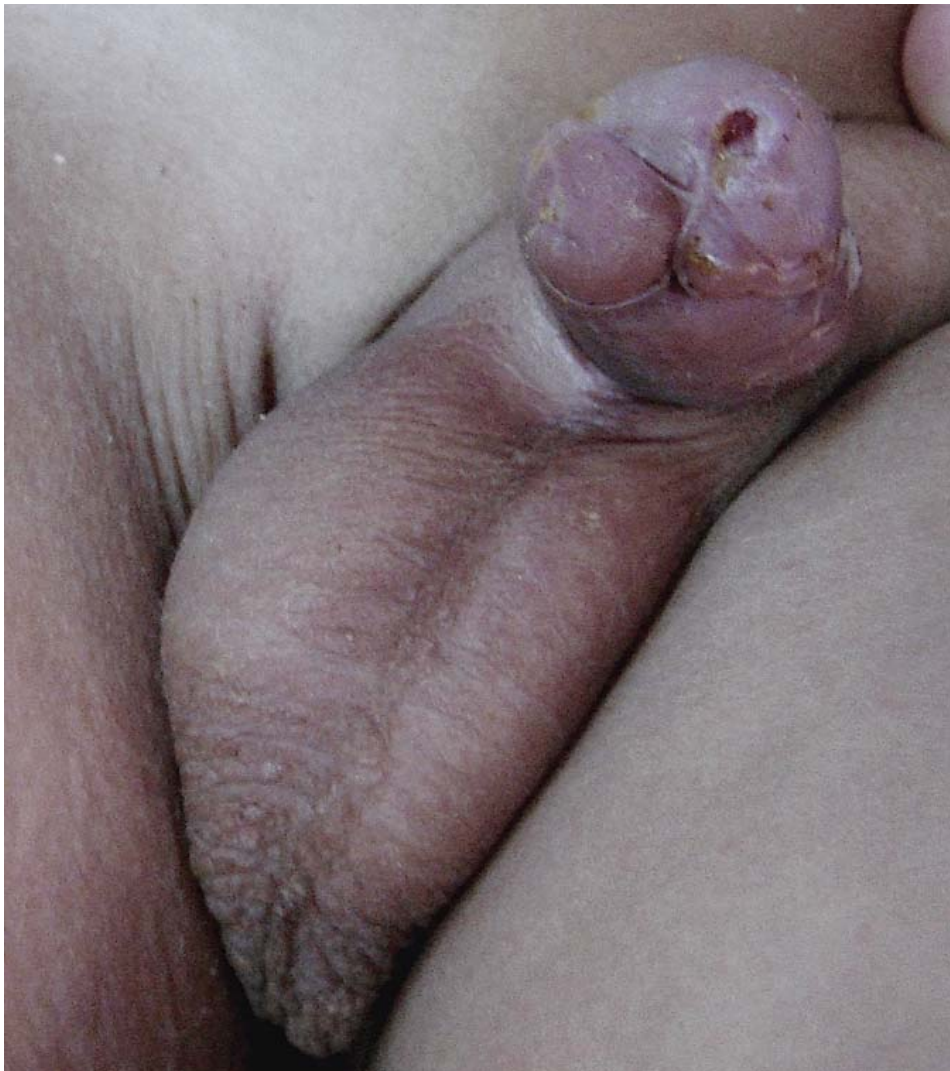

FIG. 10.4 An excess inner preputial layer at the right side of the glans.

SKIN BRIDGES

Sometimes a localized area of adhesion results in the formation of well-formed excess skin bridges between the skin of the penile shaft and the glans penis (Fig. 10.10). These epithelialized adhesions can lead to penile chordee, torsion, and later on, it may result in a painful erection due to tethering of the erected penis. Skin bridges in the ventral penile surface are usually more symptomatic than the dorsal and lateral ones. The abnormal scarring will also make the circumcised penis look ugly with an obvious disfigurement (Fig. 10.11).

Smegma often accumulates under those skin bridges, and it may form a well-capsulated cyst (Fig. 10.12).

Skin bridges could be seen as a single area of wedge like skin creeping over the glans with different sizes at

one side, or multiple scars of different shapes around the glans (Figs. 10.13 and 10.14).

Excess redundant skin after circumcision, physiologic retraction of the penis due to a suprapubic fat pad and diaper irritation of the penis may be predisposing factors.

Incidence

How such these problems arise is not completely clear, as true incidence is difficult to estimate. But some authors reported that skin bridges accounted for nearly 30% of the late complications. The rate of complications usually decreases with age, owing to the epithelial separation of the adhesions (71% of infants, 28% of 1–5 year old children, 8% of 1–9 year old children and 2% of children older than 9 years).⁴

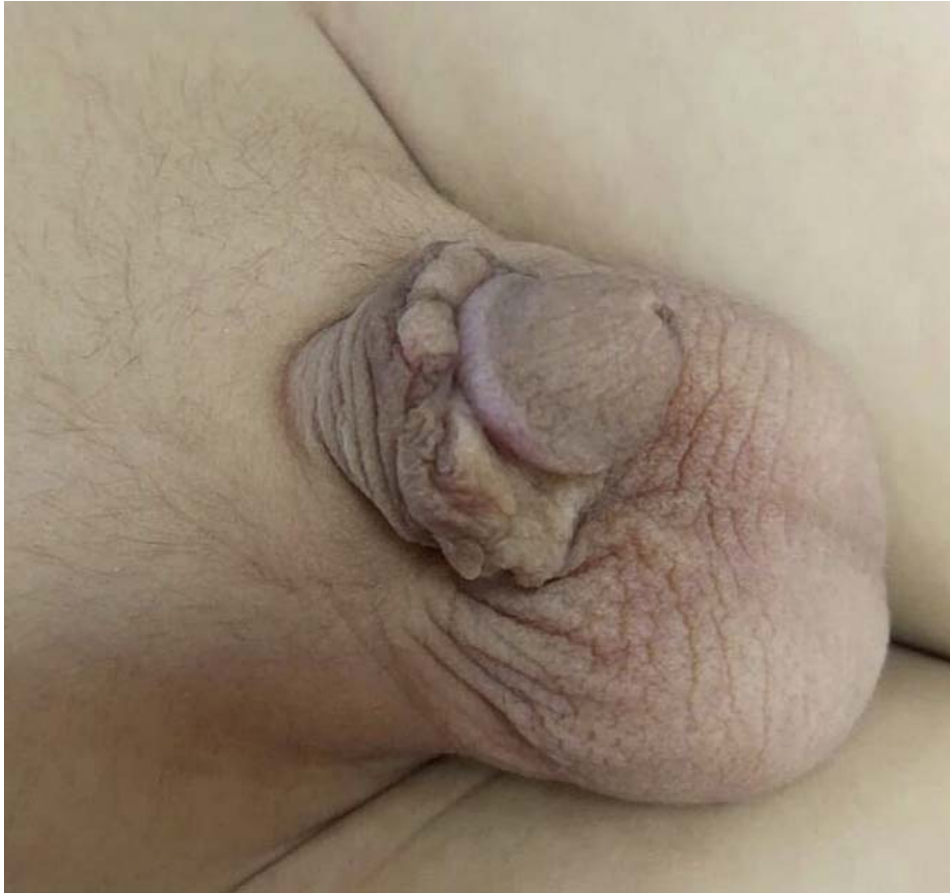

FIG. 10.5 Prominent stitch marks along the scar of circumcision.

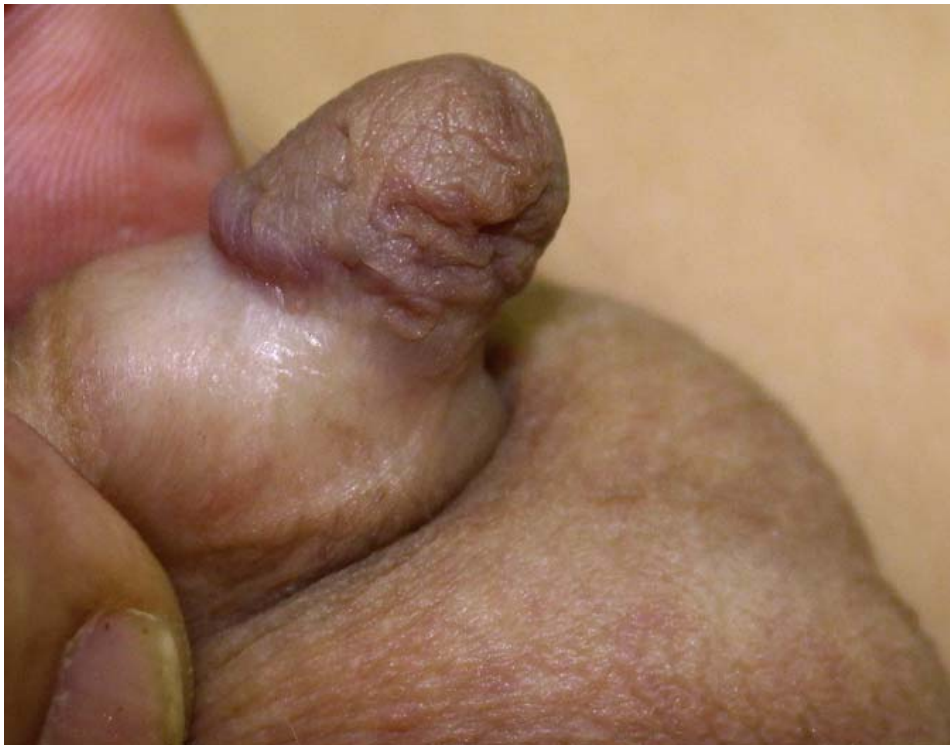

FIG. 10.6 Multiple glandular injuries leading to disfigurement.

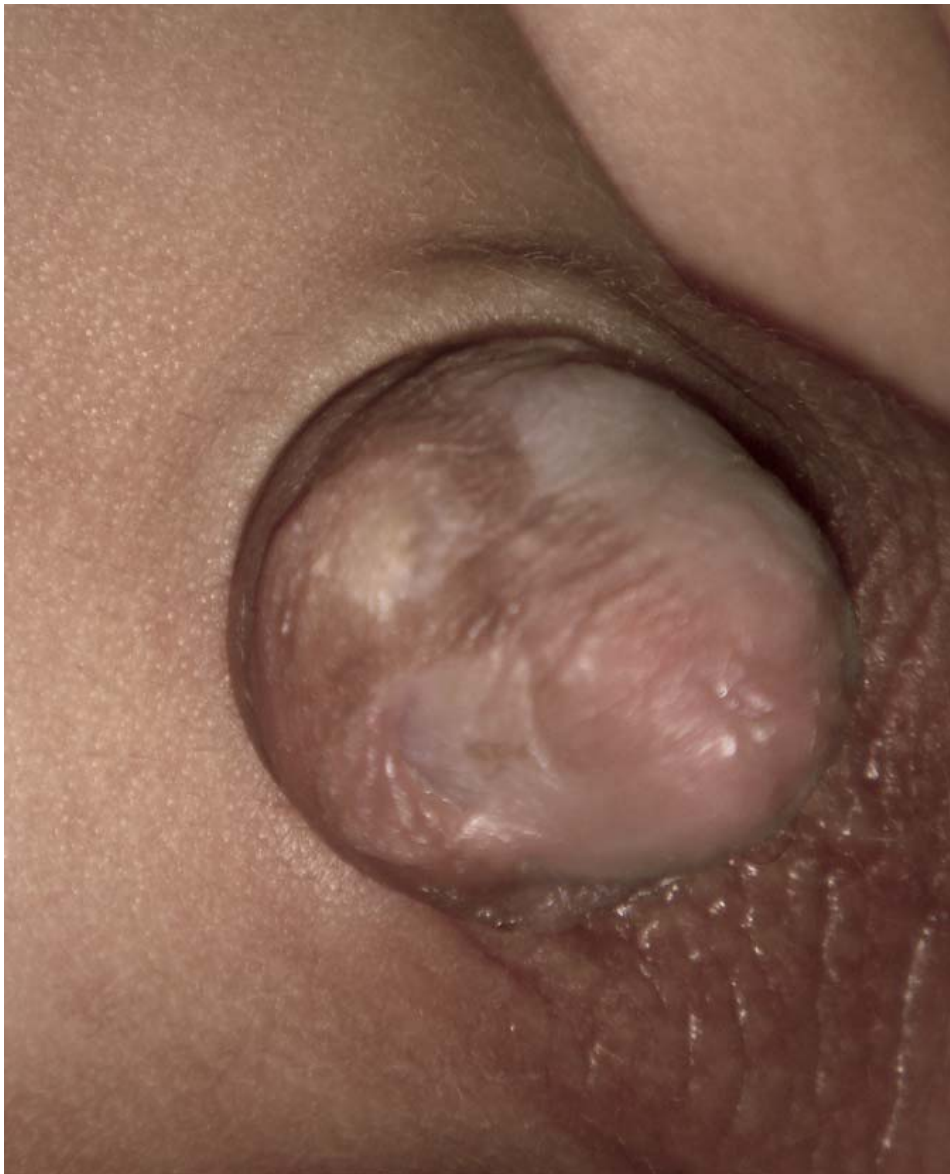

FIG. 10.7 A rare case of balanitis xerotica obliterans after male circumcision with marked penile adhesions.

Treatment

This complication could be avoided by completely freeing the inner preputial layer from the glans at the time of circumcision; also, if any glanular abrasions, injury or ulcer is detected during MC, it should be dressed and managed properly until complete healing to avoid the natural cohesion between the denuded area of the glans and the penile skin. Use of low-dose corticosteroids has been relatively unsuccessful in lysing these well-formed adhesions. The adhesions can be excised in the office with the application of local anaesthesia or in the operating room with the use of general or regional anaesthesia by suturing the

glandular and shaft defects with fine absorbable sutures (Fig. 10.15).

In my opinion, routine suturing of both preputial layers with fine stitches either continuously or with interruptions, even in neonatal MC, will protect the healing incision from such complications.

INCOMPLETE CIRCUMCISION

Nomenclature: Residual prepuce, inadequate circumcision or excess foreskin.

The high degree of variability in the appearance of penis after MC could not be related to the technique



FIG. 10.8 Extensive penile adhesion between the circumcision scar and the glans, forming a ring around the glans, with marked disfigurement.

used or to the physician using it. When operating on an infantile penis, the surgeon cannot adequately judge the appropriate amount of tissue to remove because the penis will change considerably as the child ages, such that a small difference at the time of surgery may translate into a large difference in the adult circumcised penis. Any one dealing with penile anomalies can recognize the diversity and wide variation in the normal

anatomy of different penile structures because many neonates may have a very long prepuce, which is called 'akroposthia', and some may have a deficient prepuce, with an exposed distal glans without preputial retraction, so the amount of prepuce to be removed in MC should be tailored for each baby according to the length of his prepuce. This is extremely difficult to achieve in mass circumcision or even in a hospital with a high

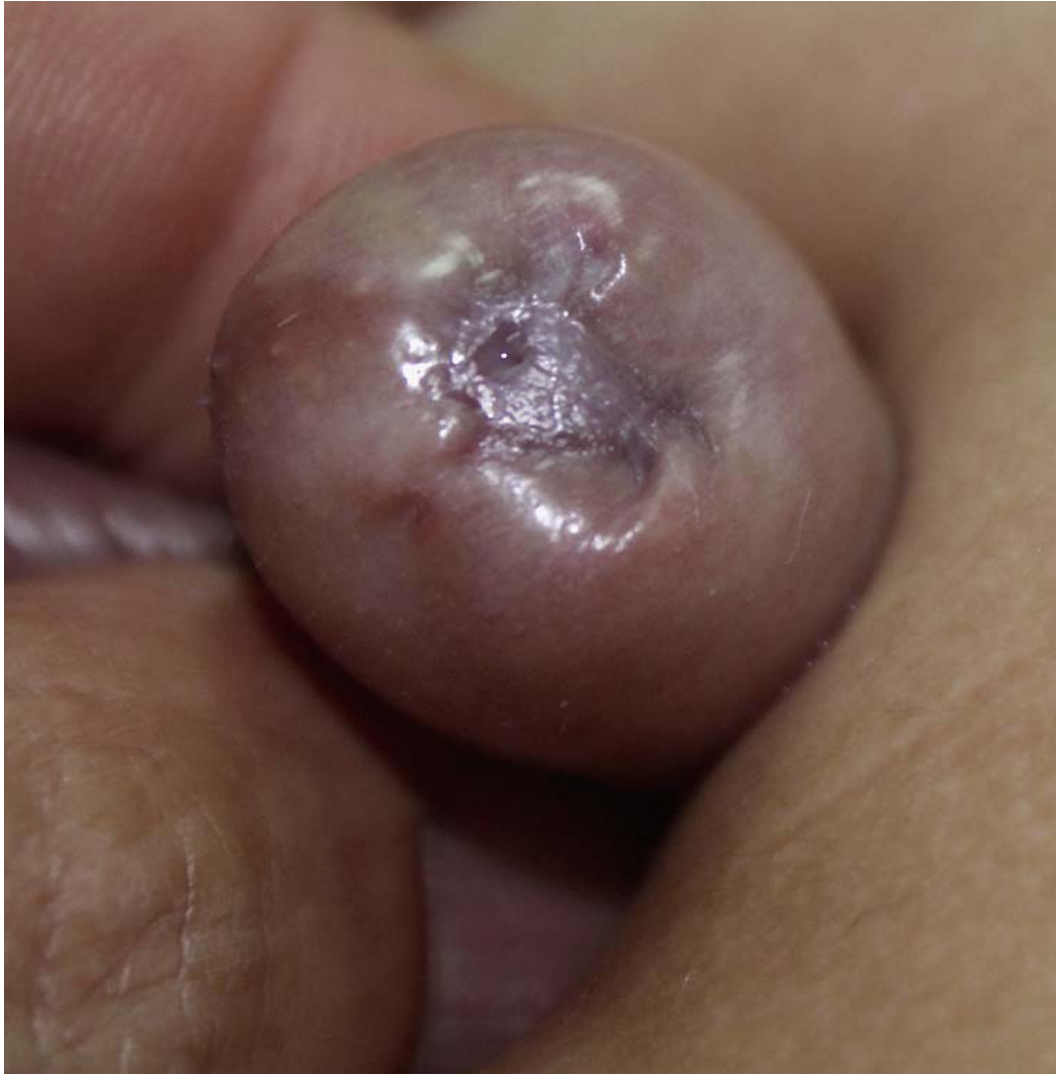

FIG. 10.9 Penile adhesions forming a scar ring with the glans around the urinary meatus, which may result in cicatricial phimosis.

number of cases. To date, there have been no published studies showing the ability of a circumciser to predict the later appearance of the penis.⁵

According to the previous studies, between 1% and 9.5% of boys circumcised at birth will have the procedure revised or redone and 2.8% of parents will complain of the cosmetic appearance.³

Leaving a short inner prepuce is achievable in open sleeve and clamp techniques (Gomco and others), but it is not possible in the traditional guillotine-type circumcision, which leaves a very long inner prepuce with a circumcision line placed in almost the middle of the penile shaft (Fig. 10.16). Unfortunately, this is still the most common technique performed by nonmedical personnel in large parts of the world.

The inner foreskin and outer foreskin are a separate entities, and not the opposite sides of a single layer of tissue. They are not attached to each other and in consequence are mobile with respect to each other. Thus it is possible to remove unequal amounts of the two layers. Understanding this point is crucial for recognition of a different circumcision styles.

If we can exclude other complications, the penile looks after different techniques of MC may be one of these two common styles:

- MC style that retained the inner foreskin (the 'high' style): The circumcision scar line of a man with the high style will be partway up his penis (Fig. 10.16). If the scar is moving freely without tightness, it is called high loose, otherwise it is a high tight one. Of course,

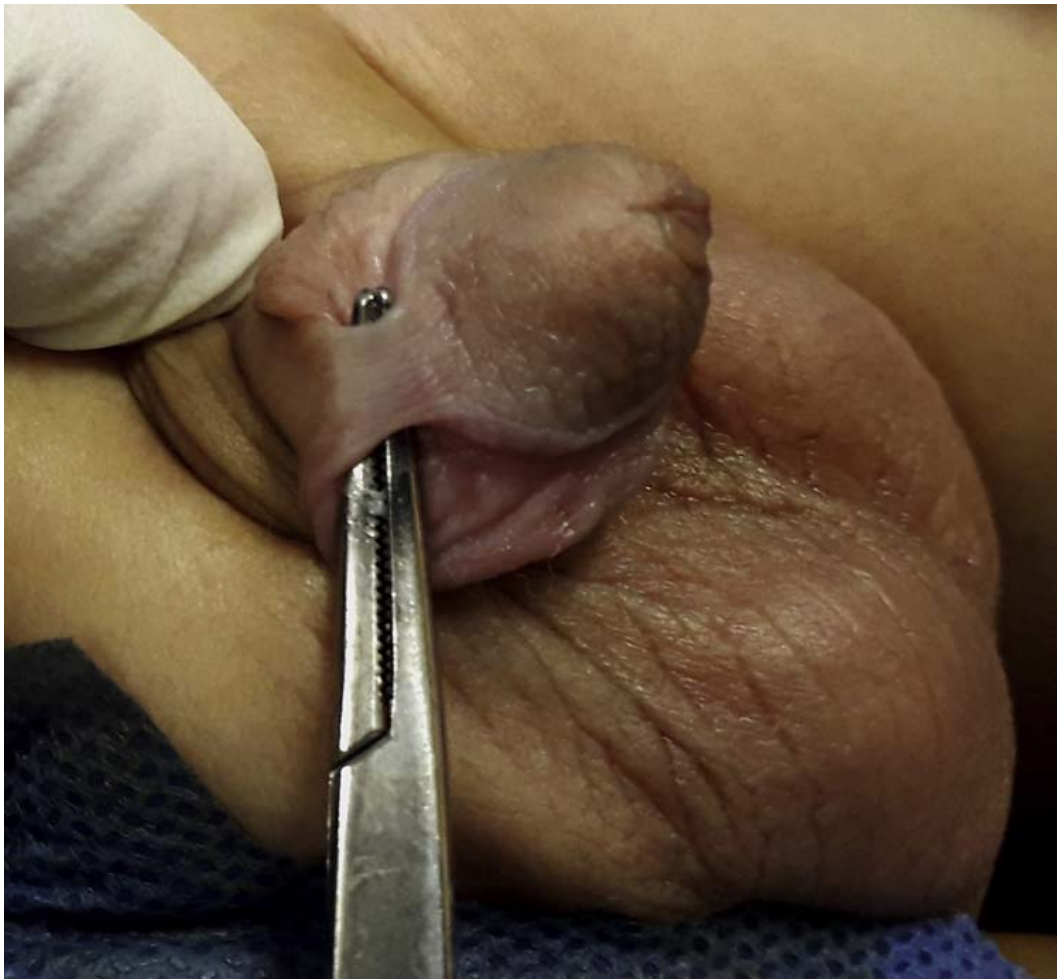

FIG. 10.10 Penile adhesions forming a well-defined skin bridge with the glans penis.

these cases should be differentiated from cases of sever skin loss, which may heal with intense fibrosis.

- MC style that removed the inner foreskin (the 'low' style): The circumcision scar line of a man with the low style will be close to the rim of his glans (Fig. 10.17). If the scar ring is tight, it may be problematic and may be considered as a concealed penis (CP) or even an acquired phimosis. A loose scar is an acceptable form, but it may be an indication for MC redo according to some parents' wishes. So the circumcised scar could be classified as
 - High loose
 - High tight
 - Low loose
 - Low tight

The amount of penile skin excised can also lead to many other complications, as insufficient or asymmetric

prepuce excision can result in a cosmetic and social dilemma for the parents and the child, especially when the child gets older (Fig. 10.2).

A circumcision that is too loose may not leave the glans completely uncovered but it will, in other words, be a partial circumcision, and this is not in itself a problem but it may not meet parental or religious expectations. However, there is one important exception, if the scar can mobilize in front of the corona then it will shrink and create secondary phimosis, which requires recircumcision. If a partial circumcision is deliberately chosen then the best approach is to remove the inner foreskin completely, so that the scar will be in the sulcus. At puberty the penis will usually outgrow the skin and leave the glans exposed, as the degree of skin covering the glans after neonatal circumcision peaks at 6 months of age.

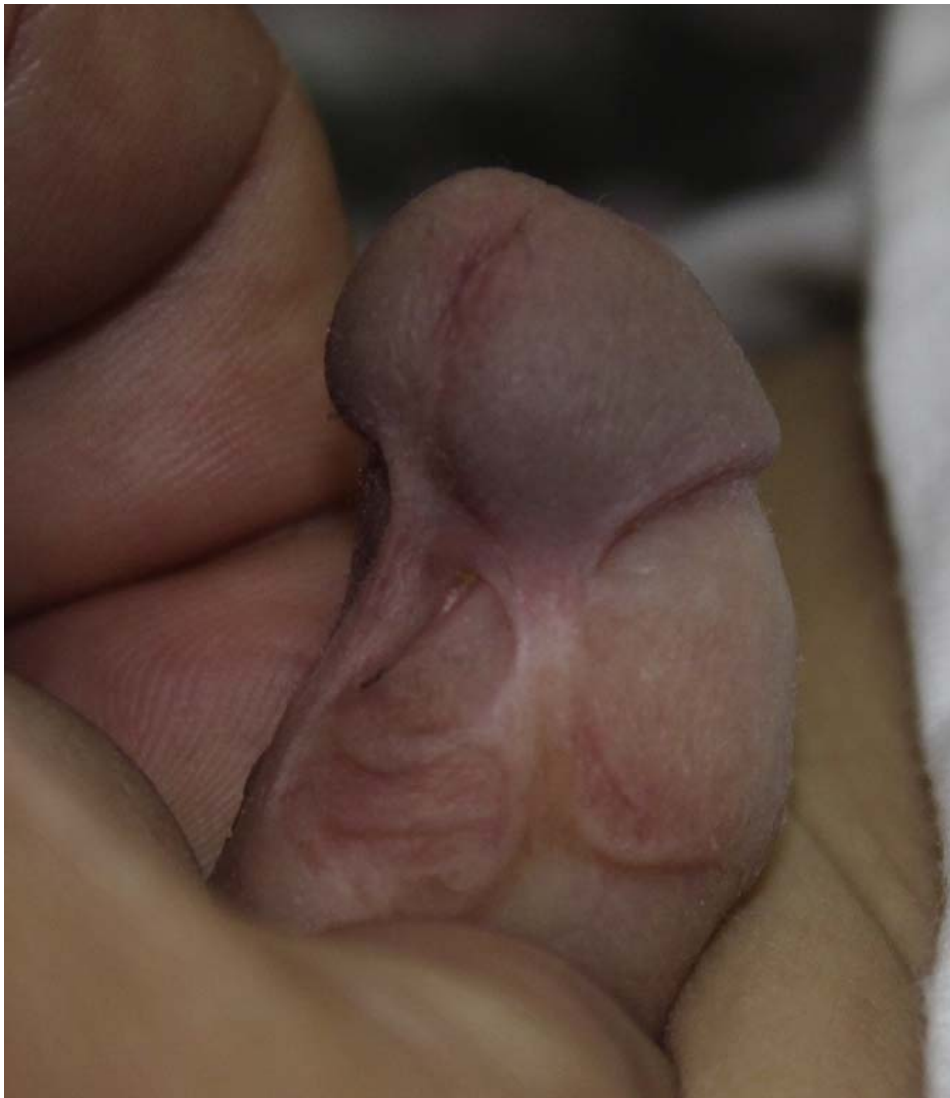

FIG. 10.11 A ventral skin bridge results in penile curvature during erection.

Management

Unlike neonatal circumcision, circumcision revision requires general anaesthesia, for which several techniques have been described. Excessive skin excision can result in penile chordee, torsion and lateral deviation. These conditions, if necessary to repair, may require penile skin flaps or Z-plasty for closure.

Excessive skin removal can also result in a trapped penis from a cicatricial scar. The trapped penis can be managed with betamethasone conservatively, vertical relaxation incision and then a formal repair. The use of 0.05% betamethasone in conjunction with manual retraction in children with a trapped penis due to a dense cicatrix of the residual foreskin distal to the glans has a 79% success in softening the cicatrix with easy

exposure of the glans or mild persistence of the cicatrix amenable to vertical relaxation incision.⁵

While many people favour retaining a lot of inner foreskin, this can sometimes cause problems. The inner skin is very thin and stretchable, and if there happens to be a lot of postoperative swelling, it can permanently stretch the skin, leaving it loose and puffy. This has no effect on penile function, but it can appear unsightly (Fig. 10.18).

If the physician succeeds to convince the parents (or sometimes the circumcised adult) not to revise the circumcision in cases of low or incomplete MC, special attention should be paid to the retained part of the prepuce. Generally, the circumcised penis requires more care than the intact penis, especially during the first

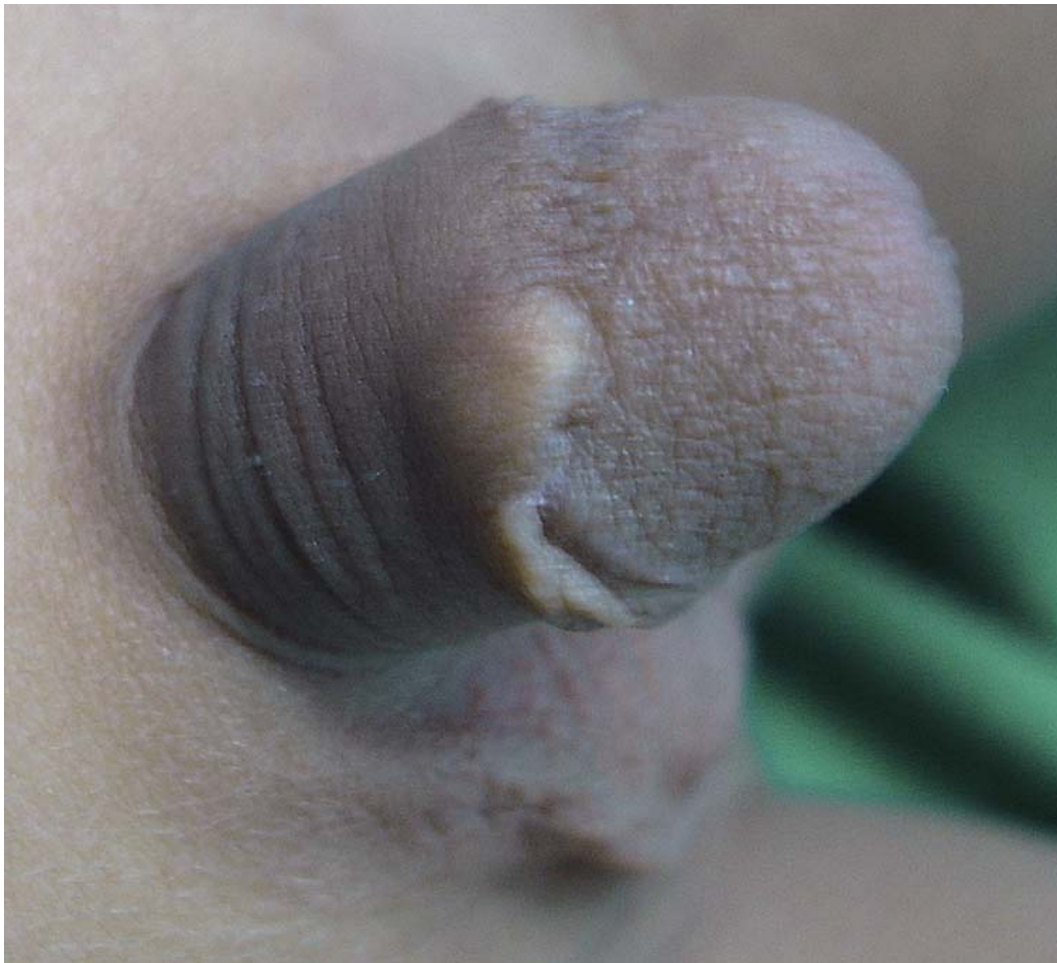

FIG. 10.12 A small smegma cyst formed under a skin bridge.

3 years of life; any skin covering the glans in circumcised boys should be retracted and cleaned to prevent adhesions and debris accumulation.

In contrast to the general belief that smegma is not present, or at least not accumulated, in circumcised boys, we encountered many circumcised babies with the same smegma accumulation and configuration as in the intact ones, especially in those children with low loose type of circumcision. So all the adverse effects of smegma will be seen in an adult with a retained long prepuce after circumcision (Fig. 10.19).

POST-MALE CIRCUMCISION CONCEALED PENIS

Generally, CP refers to an anomaly such that the penis appears to be short, even though its length is normal. CP may be divided into three groups according to the Maizels classification, which is based on the aetiologic

mechanism: buried penis, webbed penis and trapped penis.⁶⁷

One or more mechanisms may contribute to concealment in each case:

- Buried penis describes a condition in which a penis remains under the level of pubic skin because of the excessive suprapubic fat or the loose attachment of penile skin to the dartos.
- Webbed penis is a condition in which there is extra skin between the scrotal raphe and distal penis, obscuring the penoscrotal angle.
- Trapped penis refers to a condition in which a normal penis is depressed under the skin following a surgical procedure, generally circumcision, and looks concealed, and this type is our main concern herein (Fig. 10.20).

Williams et al. reported a rate of 9% CP among those applying for routine circumcision. The same study reported a 63% incidence of CP among those applying



FIG. 10.13 A wide area of skin creeping over the glans.

for circumcision revision (26% trapped penis and 37% insufficient circumcision).⁸ It is possible that one may refrain from excising sufficient prepuce in order to avoid a more complicated picture in a case with partial CP and as a result insufficient circumcision may take place. In a baby with CP, generous excision of the penile skin in an effort to make the penis visible usually leads to a crippled problem of trapped penis, with almost no local penile skin surrounding the penis, which will require flaps or grafts for correction.

This complication is commonly seen in overweight children or in those with extensive suprapubic fat and is expected to associate cases of microphallus and webbed penis.

Post-MC CPs could be classified into complete and partial concealment.

Complete

This is commonly seen in neonatal circumcision in which the penis is completely hidden and covered by either the scarred penile skin or the scarred preputial remnants (Fig. 10.20).

Partial

In this condition, the glans penis is visible but the penile shaft is partially covered by the scarred skin, and this is usually seen in older children (Fig. 10.21).



FIG. 10.14 Multiple skin bridges.

Penile entrapment by the circumcision scar may be complicated by an ascending urinary tract infection (UTI), balanitis and may lead to a cicatricial phimosis.

In children with a secondary CP, but without phimosis, observation may be an option, as the cosmetic appearance tends to improve with age and surgery should be delayed until the child is at least 3 years of age. Borsellino et al.⁹ reported that a staged revision surgery was required in a majority of their cases because the penile shaft skin was also excised along with the prepuce.

POST-MALE CIRCUMCISION PHIMOSIS

Nomenclature: Cicatricial phimosis, acquired phimosis, preputial stenosis.

Post-MC phimosis is a sort of penile adhesion, with extensive scarring distal to the urinary meatus, covering the glans penis completely with inability to retract the preputial remnants proximally (Fig. 10.22).

When operating on the infantile penis, the surgeon cannot adequately judge the appropriate amount of tissue to remove because the penis will change considerably as the child ages, such that a small difference at

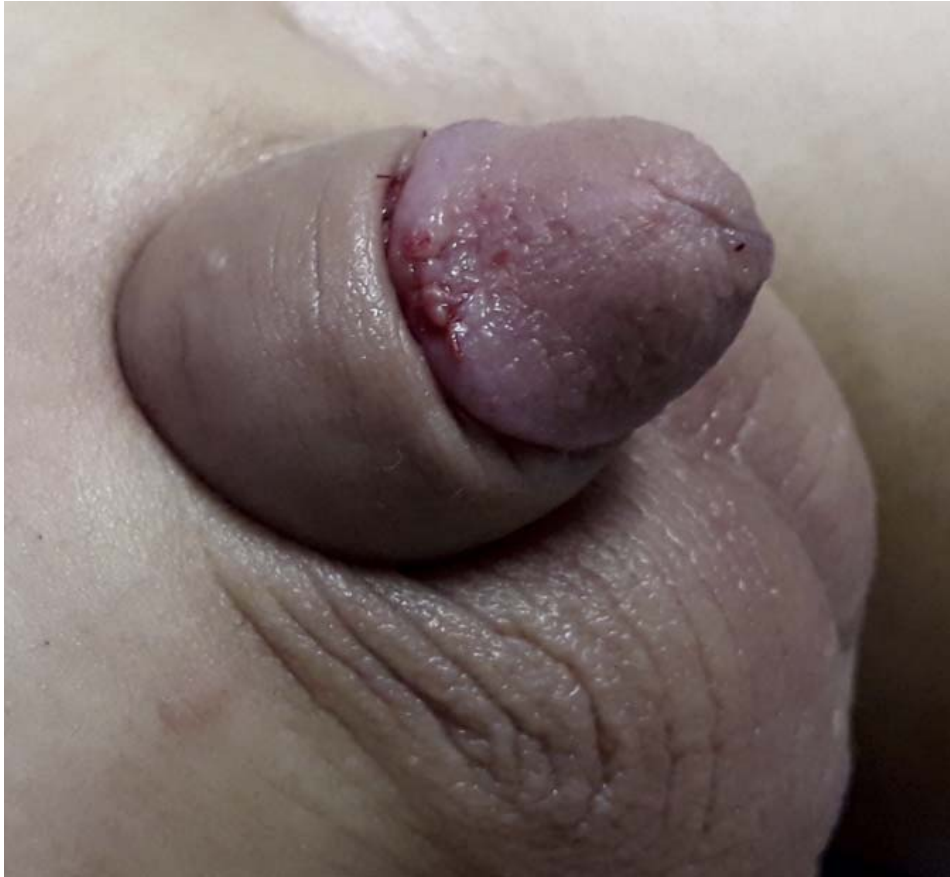

FIG. 10.15 Surgically excised skin bridges, and fine stitching of the preputial and glandular defects.



FIG. 10.16 High loose male circumcision with excess inner prepuce.

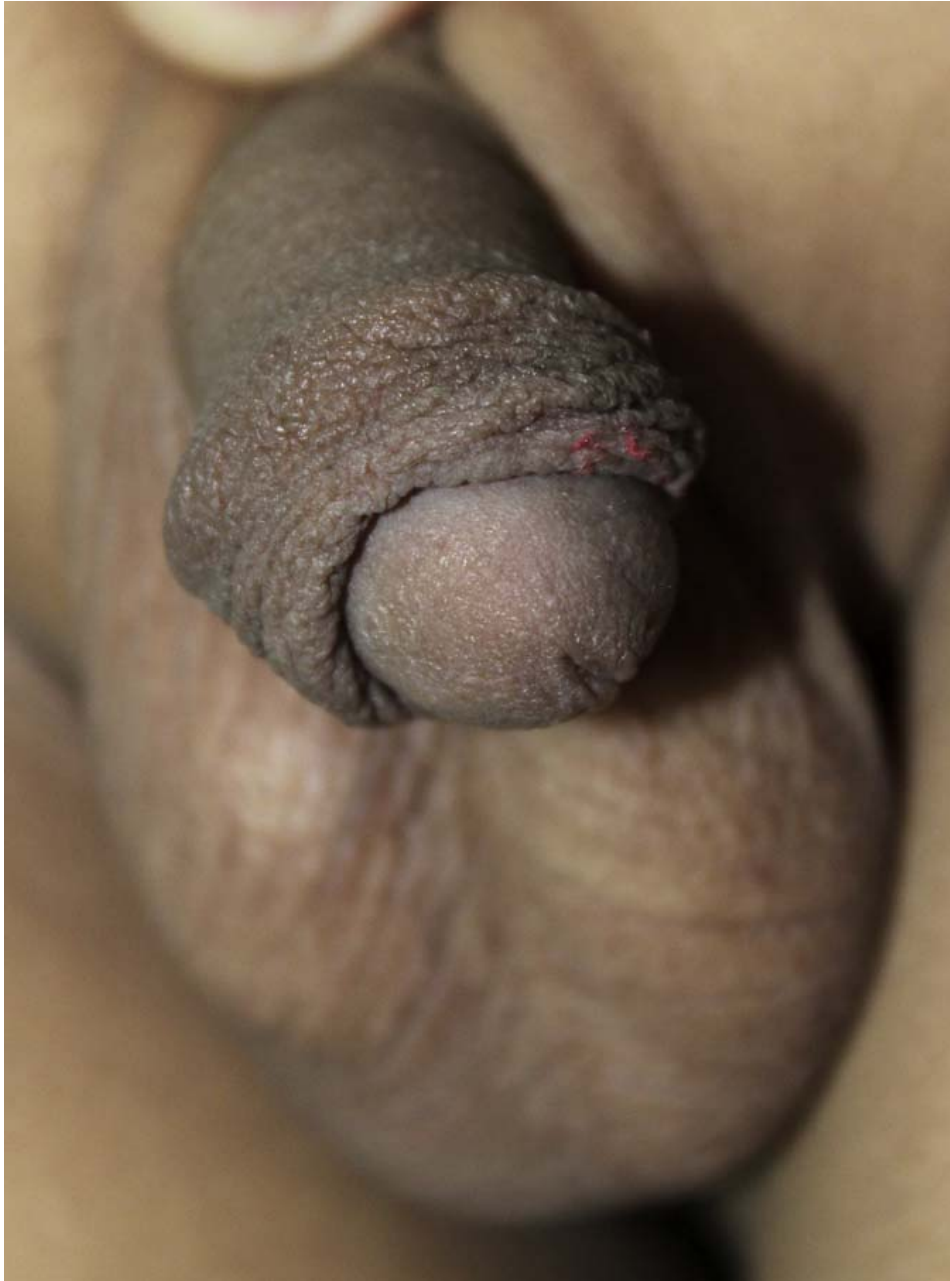

FIG. 10.17 Low loose male circumcision with excess of both the preputial layers, but without constriction.

the time of surgery may translate into a large difference in the adult circumcised penis. Phimosis with a trapped penis is an infrequent but important complication of circumcision. This condition is more likely to occur in older infants and those with poor attachment of the penile skin to the shaft.

Incidences of 0.32%, 0.4% and 1% have been reported for preputial stenosis resulting from neonatal circumcision. Although the exact incidence of preputial

stenosis (phimosis) in boys with intact penis is unknown, it is most likely between 0.9% and 1.9%.¹⁰

Penile inflammation (balanitis) may be more common in circumcised boys with preputial stenosis than in uncircumcised children with phimosis. The common finding of subpreputial debris in circumcised infants may reflect inadequate hygiene; these debris usually consisted of lint, dirt, talcum powder, stool and detritus. The association between subpreputial debris



FIG. 10.18 Incomplete male circumcision, with a long inner prepuce, looks puffy and inflamed.

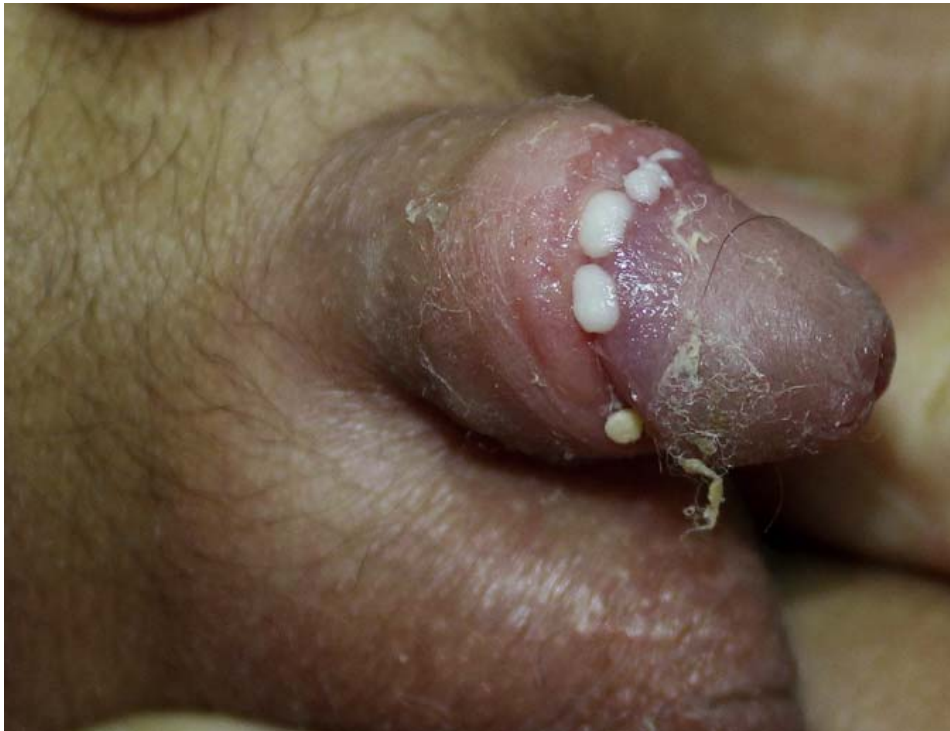

FIG. 10.19 A smegma collection with dirt in a circumcised boy.

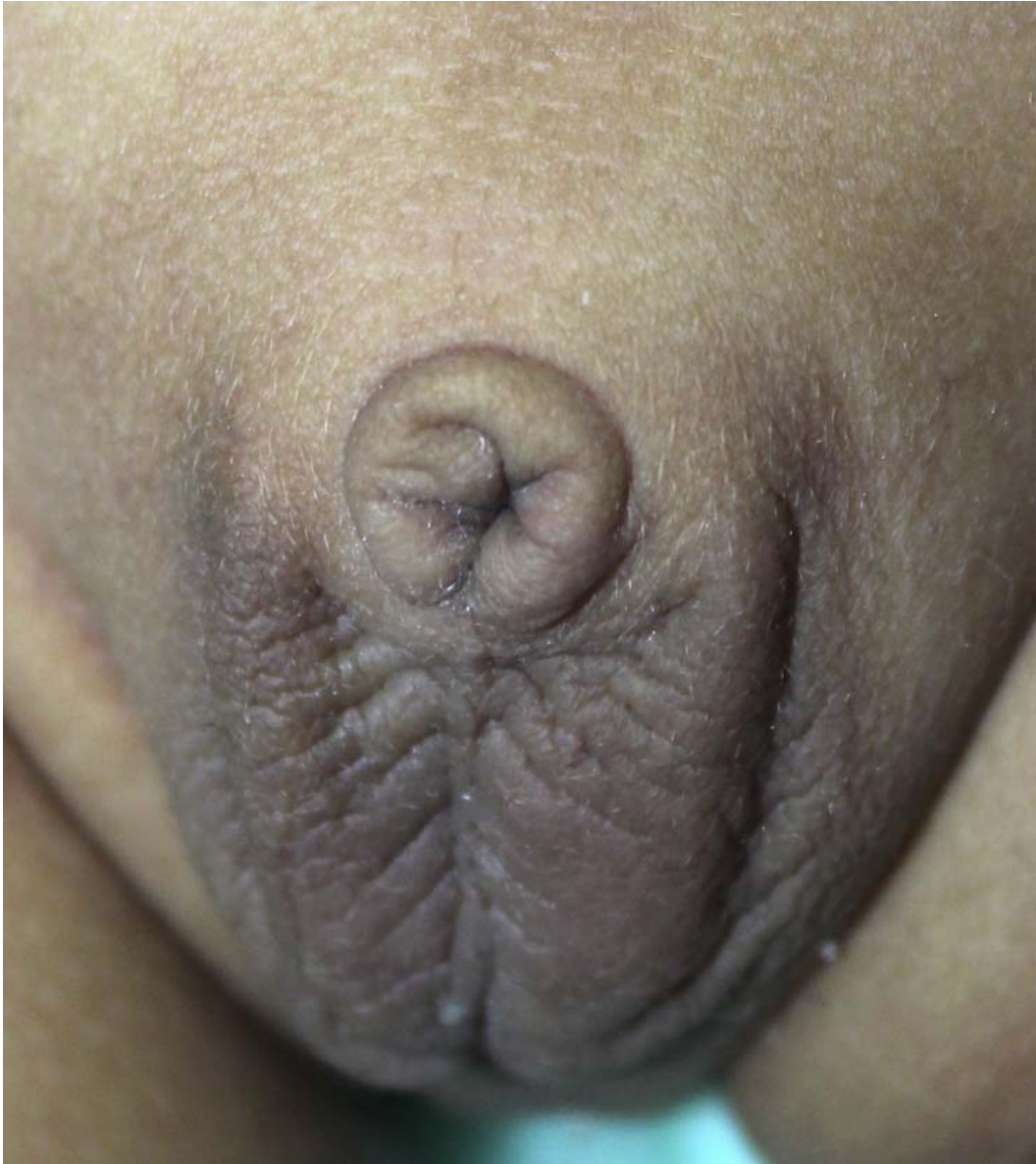

FIG. 10.20 A completely concealed penis a few months after male circumcision.

and coronal adhesions implicates poor hygiene as a possible cause. In the normal penis, muscle fibres are arranged in a whorl to form a sphincter that keeps unwanted contaminants out. Urine swirling under the prepuce in a normal infant before expulsion flushes any contaminants from the subpreputial space and may explain the paucity of findings in this population. Subpreputial debris may have been under-reported in young boys with intact penis because forcible retraction of the foreskin, which is a harmful practice, was not frequently performed.¹⁰ Difficult micturition is a

common symptom, and UTI and even urinary retention may complicate the case (Fig. 10.23).

Treatment

Unlike the treatment of primary phimosis, application of local corticosteroid cream does not cause separation of secondary glanular adhesions after circumcision.¹¹ Early recognition allows outpatient treatment with excellent results, avoiding operative intervention with general anaesthesia, by genital separation of the scarred tissue from the glans and widening of the stenosed hiatus.

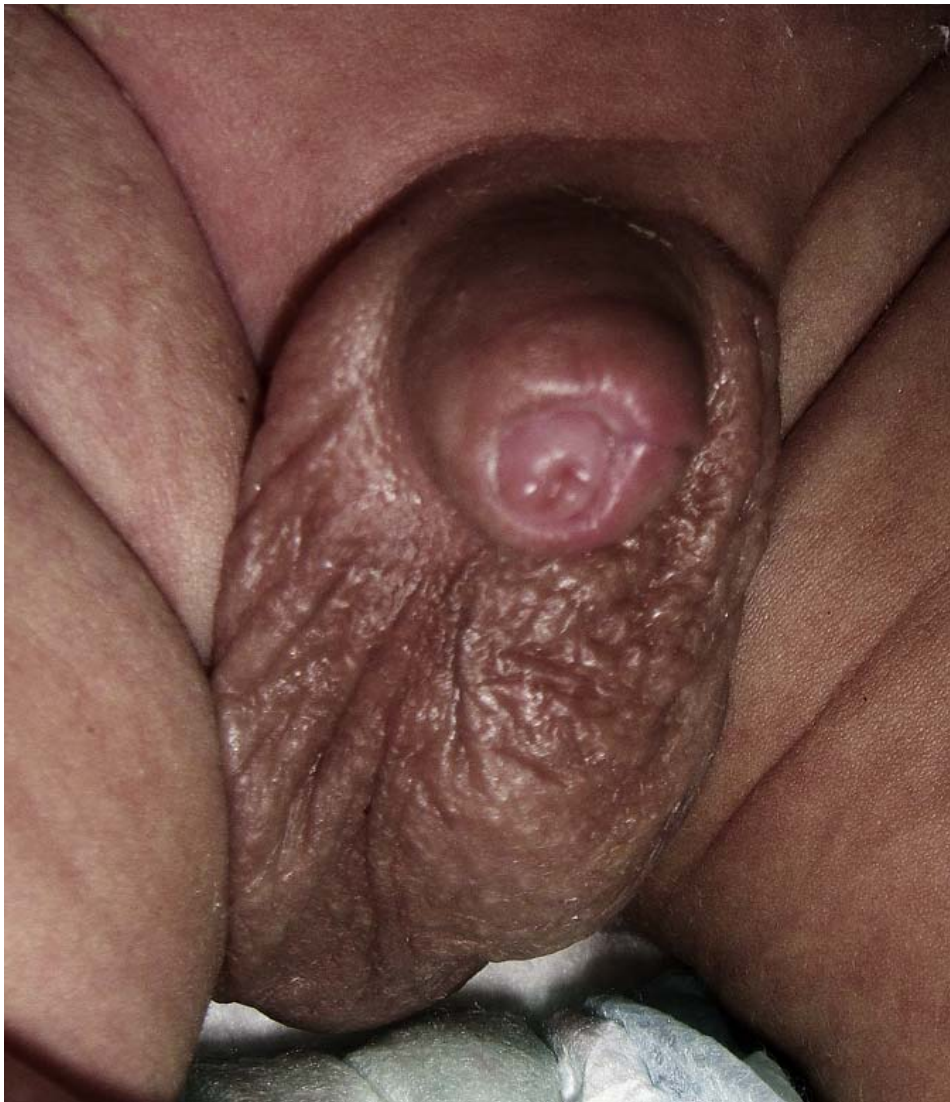

FIG. 10.21 A partially concealed penis with only visible glans penis.

In difficult and neglected cases, repair is scheduled electively under general anaesthesia and is best started by marking the part of skin to be removed precisely and a proximal incision applied, removing the redundant skin and preputial membrane as separate layers starting from up and going down to the meatus. But great caution should be exerted to avoid excessive skin removal, and the technique can be accomplished by fine stitching of the penile skin with the internal preputial remnant rim (Figs. 10.24 and 10.25).

A special entity may be encountered in adults suffering from BXO who were managed by circumcision as a treatment modality. As a few cases may develop cicatricial phimosis if the prepuce is removed incompletely and balanitis recurs, adhesions between the

glans and the prepuce are also common and these adhesions are difficult or impossible to separate. Such cases could be managed by leaving a fine layer of dartos covering the glans rather than denuding it, and the residual epithelial cells in this layer are left to recover the glans over the following weeks.¹²

PARAPHIMOSIS

Paraphimosis is a true urologic emergency that occurs in uncircumcised men when the foreskin becomes trapped behind the corona of the glans penis, which can lead to strangulation of the glans as well as painful vascular compromise, distal venous engorgement, oedema and even glandular necrosis. Phimosis, by comparison, is

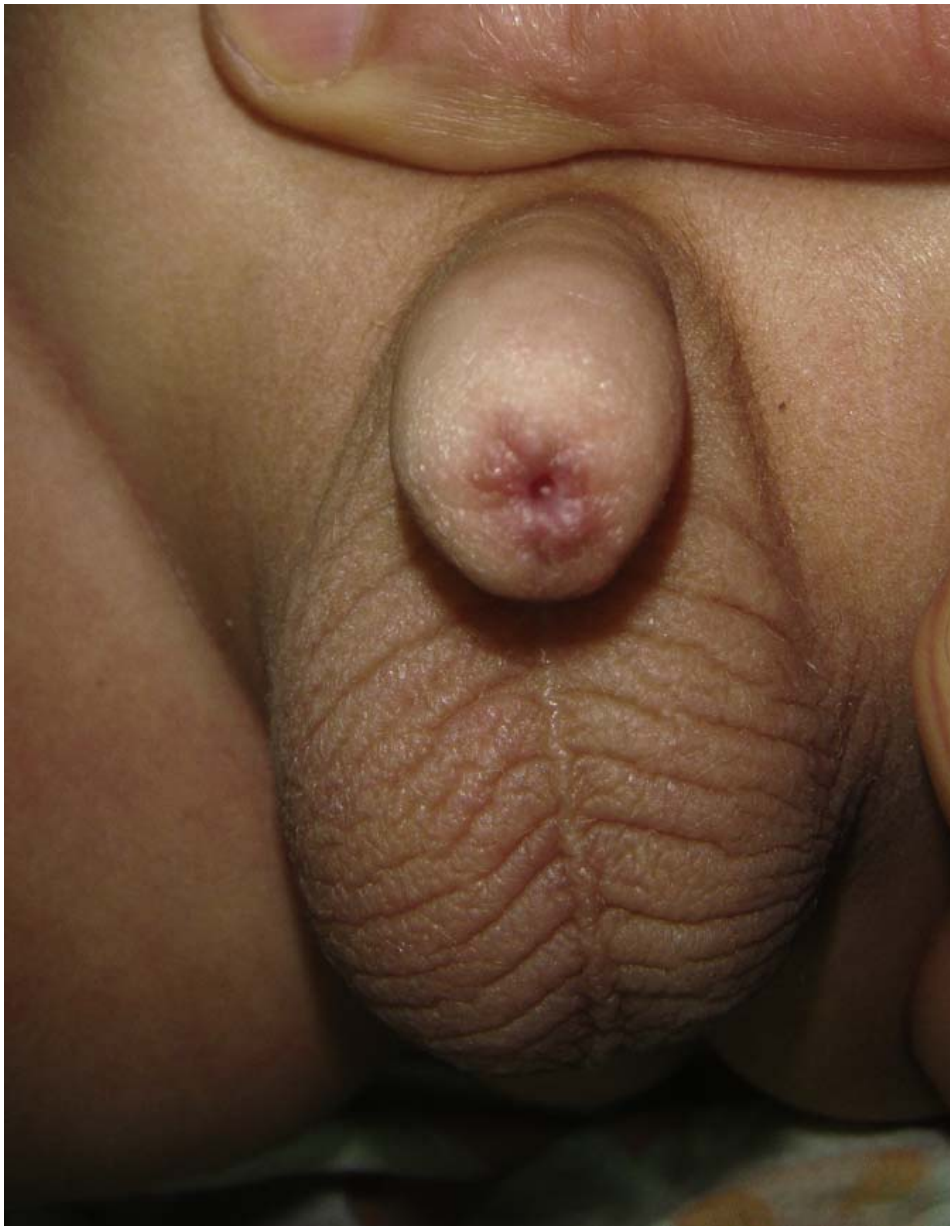

FIG. 10.22 Post-circumcision cicatricial phimosis.

the condition in which the foreskin is unable to be retracted behind the glans penis (Fig. 10.26).

Paraphimosis could happen because boys have been encouraged to retract the foreskin for physiologic phimosis by parents or medical staff.

Paraphimosis commonly occurs iatrogenically when the foreskin is retracted for cleaning, for placement of a urinary catheter, during a procedure such as cystoscopy or during penile examination. Iatrogenic paraphimosis is an acute complication of MC in neonates and children when the circumciser fails to reposition the

prepuce after initial retraction during the procedure. This complication is not related to the aesthetic complication but is discussed herein for its relation to phimosis.

Incidence

In uncircumcised children, aged 4 months to 12 years, with foreskin problems, paraphimosis (0.2%) is less common than other penile disorders such as balanitis (5.9%), irritation (3.6%), penile adhesions (1.5%) and phimosis (2.6%).¹³

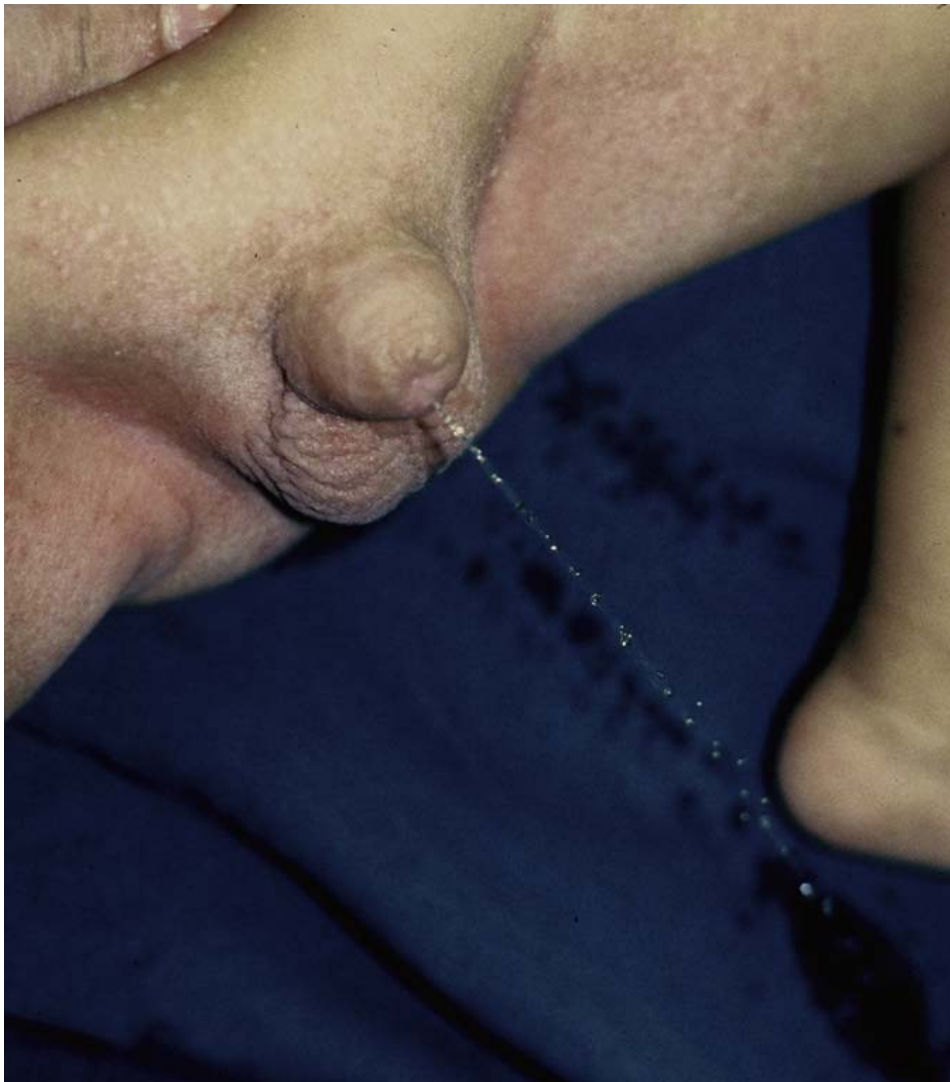

FIG. 10.23 Difficulty in micturition with acquired phimosis.

There is no estimation of the incidence of paraphimosis, which complicates the procedure of MC, but we dealt with many cases referred from the primary care centres with a strangulated preputial hiatus behind the coronal sulcus after different procedures of circumcision.

Factors that may predispose to paraphimosis include the following:

- Forcible retraction of prepuce, while the baby had different grades of phimosis.
- Babies with congenitally tight preputial opening without inflammation.
- Neonatal circumcision by inexperienced personnel.
- It is not a rare complication during circumcision of children with blood-related diseases (Fig. 10.27).
- Paraphimosis caused by dislodgement of the plastic ring represents 41.8% of complications among

children circumcised by the Plastibell technique, a complication that was responsible for the highest rate of reoperation.¹⁴

Sequelae

Paraphimosis encountered during routine MC is a controllable complication and easy to be managed without any sequel, if treated immediately or referred to specialized centres. But glans penis ischaemia or necrosis caused by paraphimosis is a rare complication of a urologic emergency, with a few cases were reported in the literature.¹⁵

Management

In most instances, manual compression can reduce the preputial oedema within the first few hours; however,

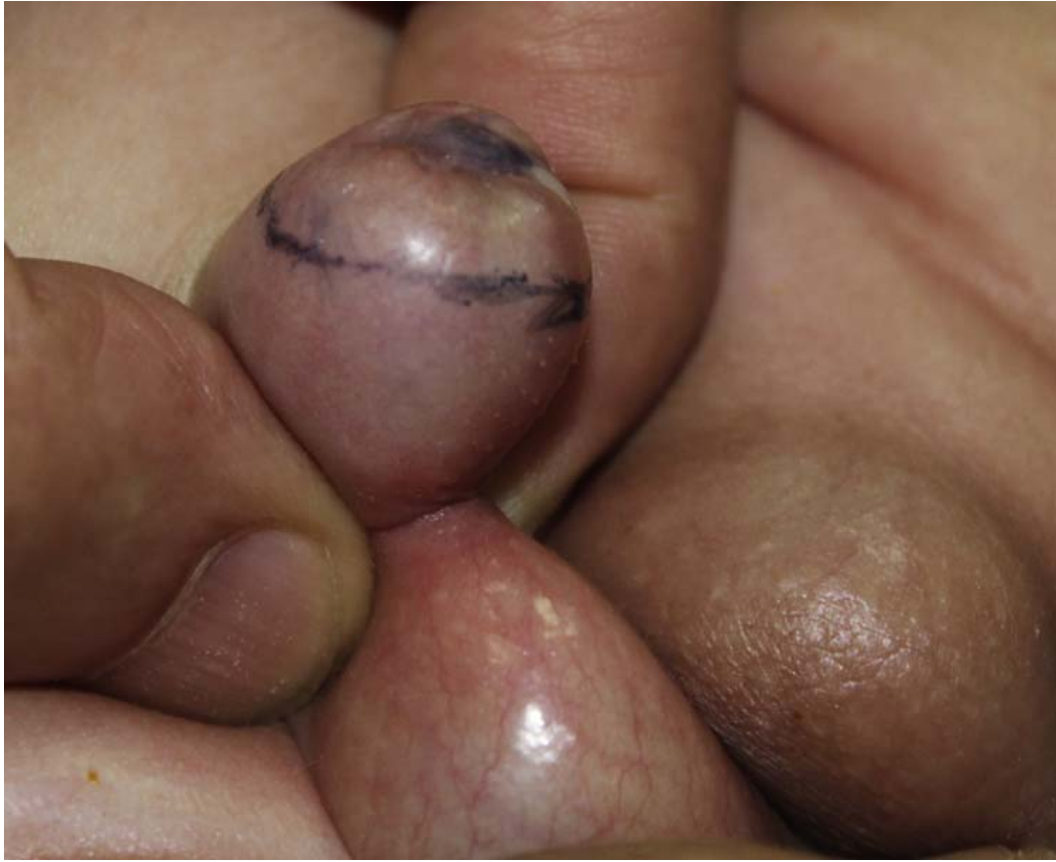

FIG. 10.24 Marking the proposed incision before correction of cicatricial phimosis.

enthusiastic attempts without adequate analgesia and sedation should be avoided, as they are distressing, are likely to fail and may make further examination or treatment interventions very difficult. Various techniques are described to treat this condition, including applying granulated sugar to the penis, adding multiple punctures to the oedematous foreskin before compression, injecting hyaluronidase beneath the narrow band to release it and wrapping the distal penis in a saline-solution-soaked gauze swab and squeezing gently but firmly for 5–10 min. Thereafter, physicians are supposed to push forcefully on the glans with the thumbs, while pulling the foreskin with the fingers. However, an emergency dorsal slit may be necessary in late cases. Generally, some authors advise completion of circumcision for paraphimosis, whereas others insist that circumcision is not advisable and could be postponed or deferred as the foreskin is oedematous and other major injuries may supervene.¹⁶

KELOID FORMATION

Since Warwick and Dickson¹⁷ firstly described their experiences with a post-circumcision keloid in 1993, only a few cases have been reported so far, but it is expected that many cases may escape proper diagnosis and reporting.

Keloids are benign, hyperproliferative scar tissue growths characterized by excessive deposition of collagen and other extracellular matrix components.

Although the exact pathogenetic mechanisms are still unknown, extracellular matrix abnormalities, aberrant collagen turnover, mechanical tension and genetic immune dysfunction have all been proposed as pathogenetic hypotheses. In addition, fibroblast cells derived from keloid tissue display an increased proliferation and density, among many other characteristics.

The most likely cause of post-MC keloid was the postoperative dehiscence resulting in prolonged wound healing in a genetically predisposed individual.

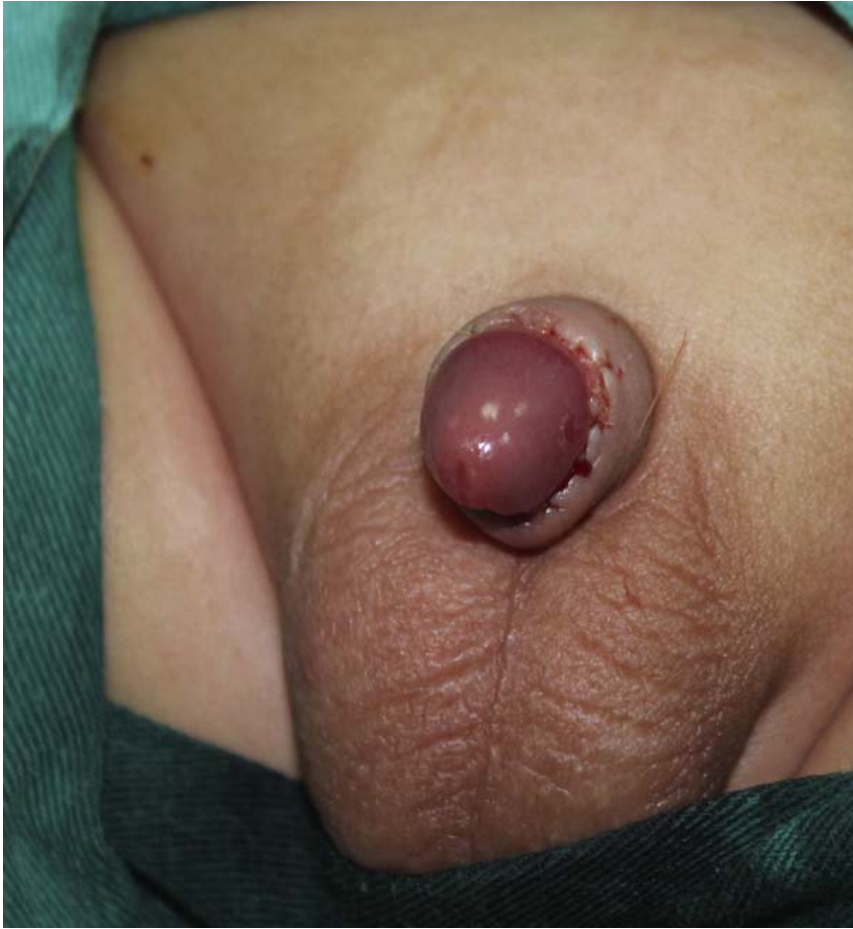

FIG. 10.25 After removing the excess constricting skin in cicatricial phimosis, fine absorbable stitches are applied.

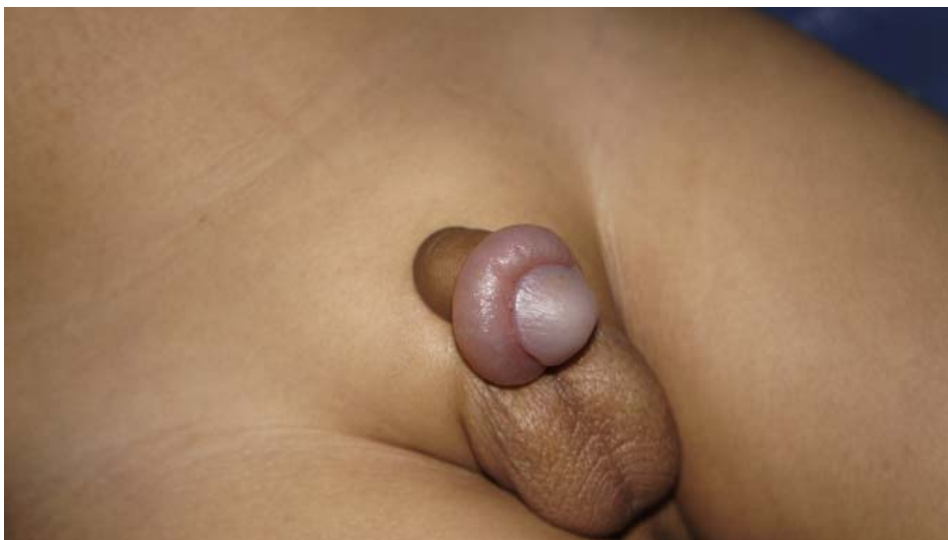

FIG. 10.26 A case of paraphimosis with an oedematous constricted prepuce behind the coronal sulcus.

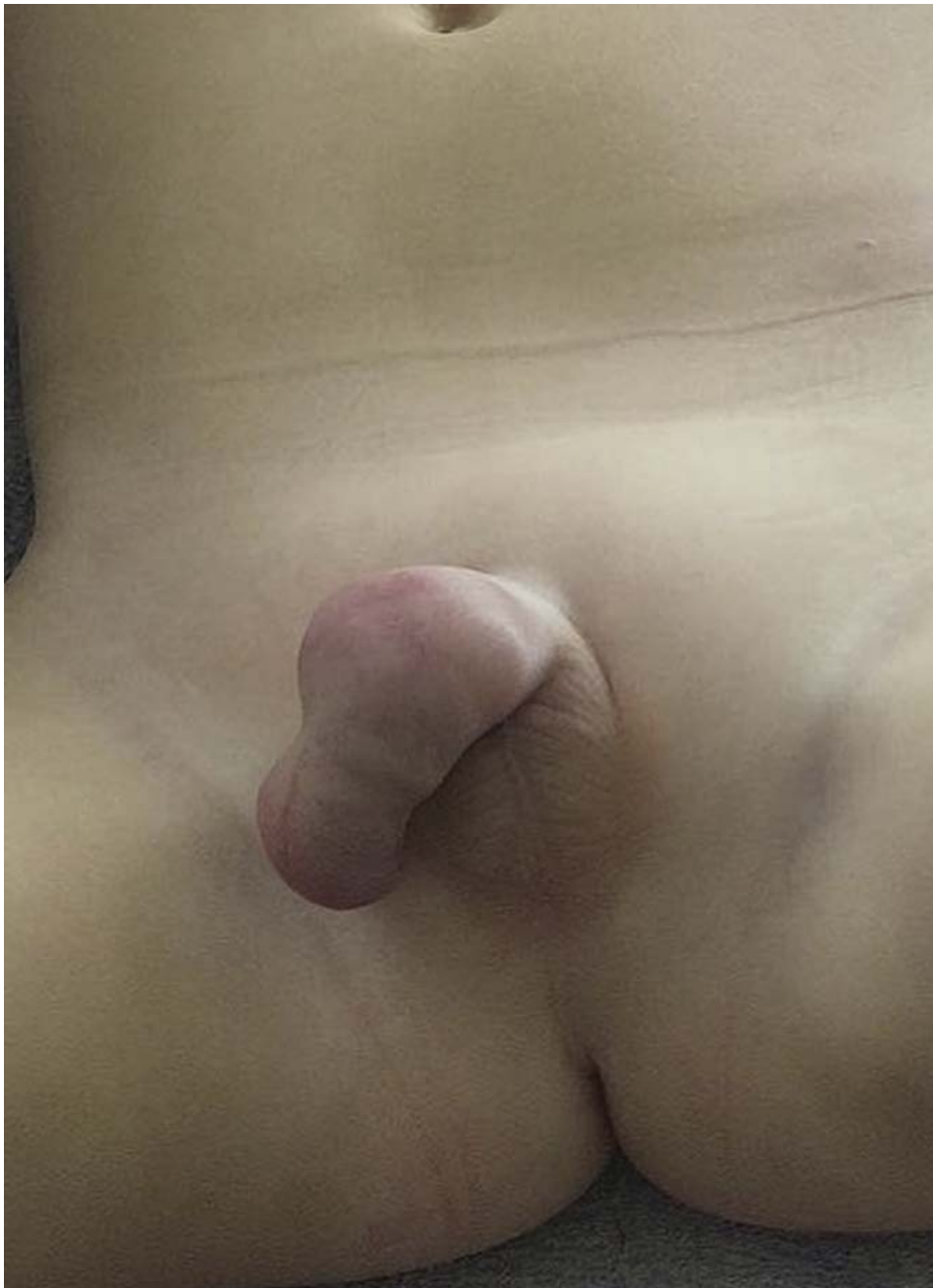


FIG. 10.27 A haemophilic child with an oedematous prepuce after reduction of paraphimosis.

Although keloid formation has been documented to be most frequent in patients between the ages of 15 and 45 years, only a few cases were reported below 12 years of age.¹⁸

Clinically a keloid is an abnormal development consisting of a raised, firm, thickened, red piece of scar tissue. Such abnormal scar at the site of circumcision creates a grotesque deformation of the organ, with

obstruction of its function. Different forms of keloid, either localized or circumferential, had been reported after MC (Fig. 10.28).

Like other keloids of the body, the post-MC keloid seems to be more common in the black races. The predisposing factors are prolonged wound healing, foreign body implant during circumcision and rough manipulation of the delicate penile skin.

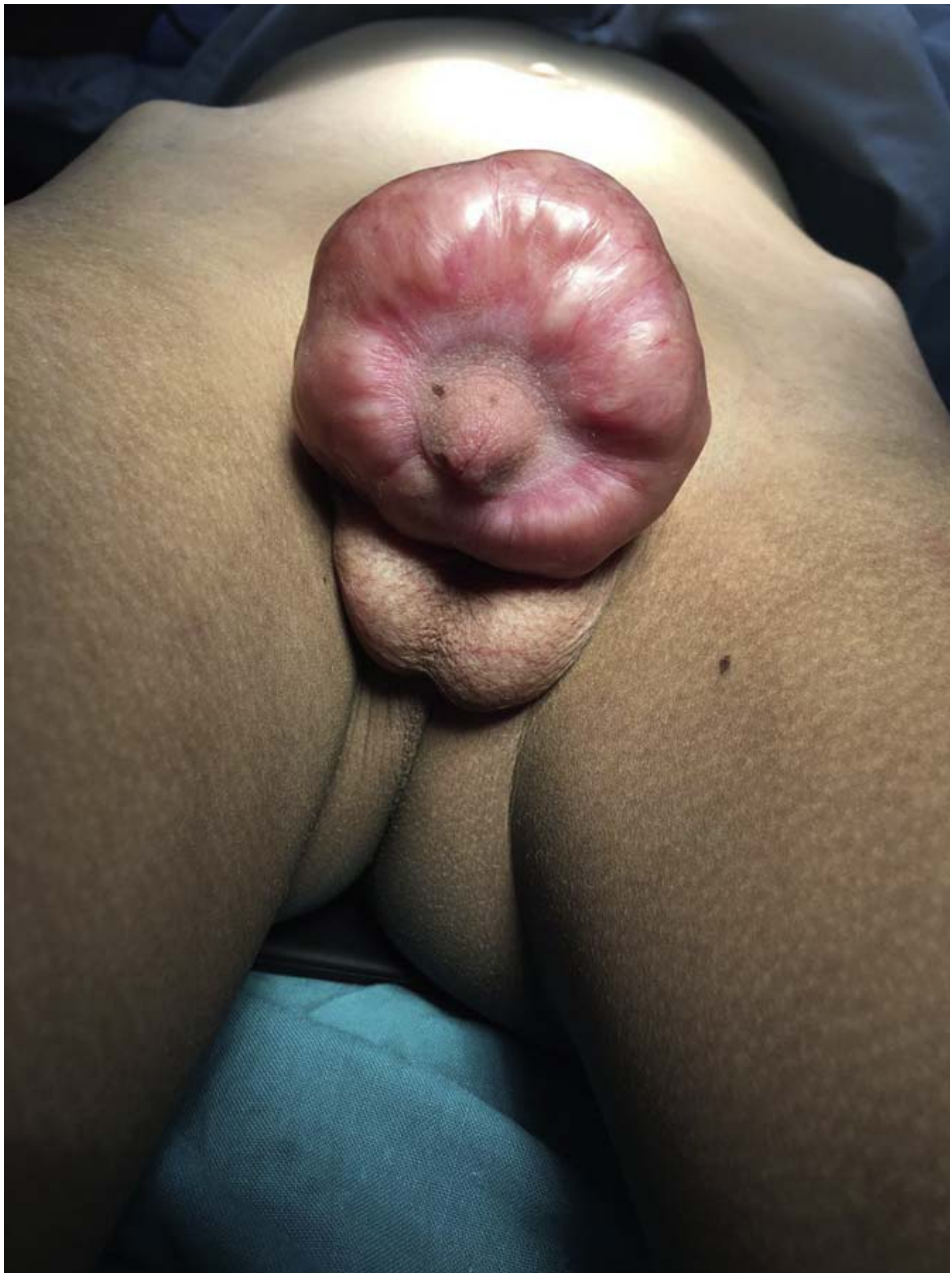


FIG. 10.28 Extensive circumferential keloid developed at the circumcision scar.

Less extensive prominent scars can occur with severe fibrosis around the coronal sulcus, and mild forms of hypertrophic scar of the healing wound after circumcision are not rare, but uncommonly reported. We diagnosed a few cases with a localized area of hypertrophic scar, especially in older children; such cases may respond to prolonged use of a potent corticosteroid, without a need for surgical intervention (Fig. 10.29).

Keloid excision with or without skin grafting is indicated as a different postoperative measure to avoid recurrence of a keloid tissue. Radiation therapy is contraindicated in children and is not desirable for penile keloids because of the close proximity of germ cells. Intralesional corticosteroid injection decreases fibroblast proliferation, collagen synthesis and suppresses pro-inflammatory mediators. The most commonly

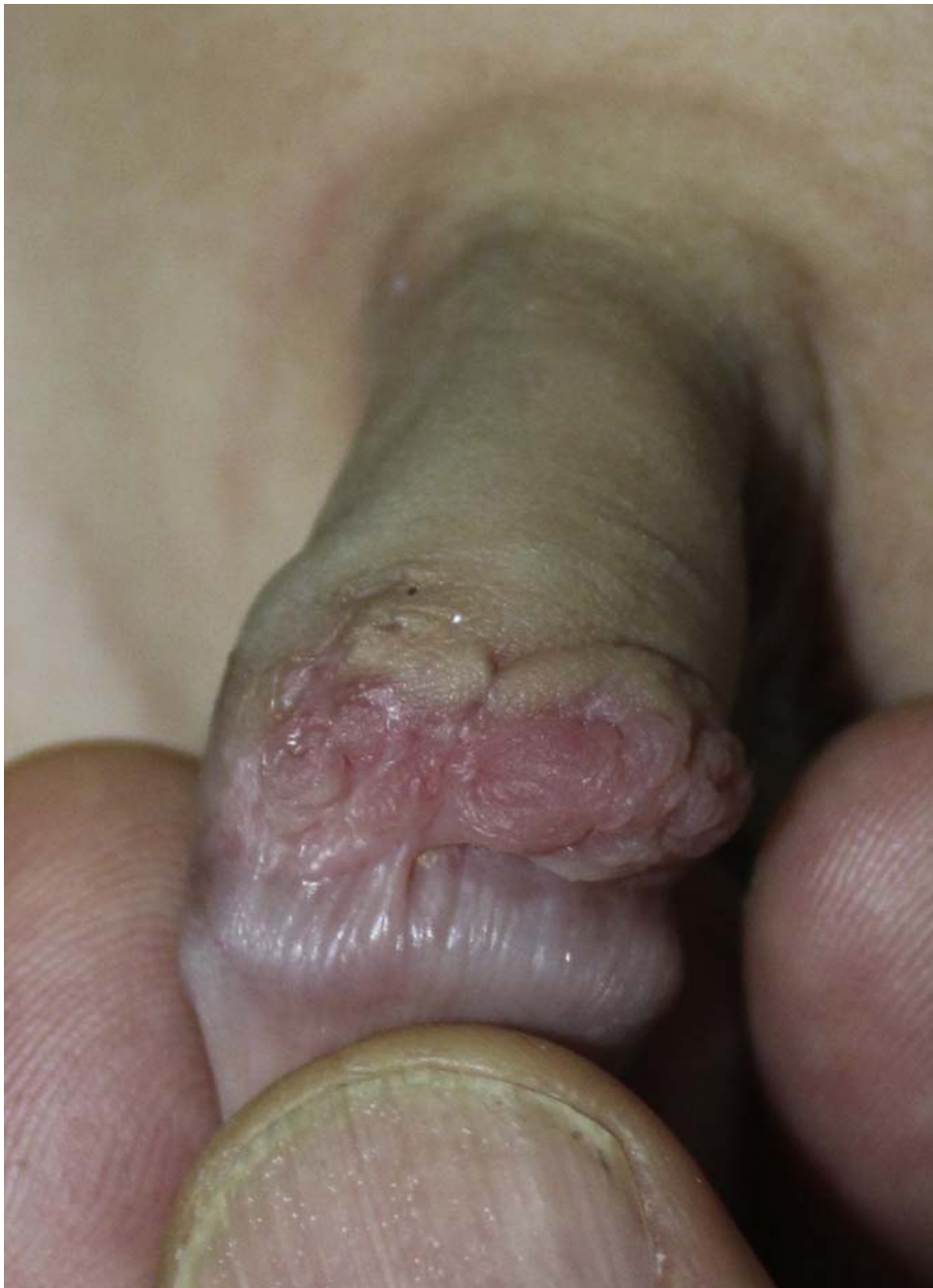

FIG. 10.29 A localized hypertrophic scar after circumcision.

used drug for steroid injection is triamcinolone acetonide suspension at a dose of 5–10 mg/mL, which is injected intralesionally.¹⁹

SUTURE MARKS

Post-MC suture marks are sometimes termed as spitting sutures, which are detected weeks to months after surgery if the body rejects the sutures (again, from the

stitches not absorbed as intended) and attempts to remove them by pushing the stitches out to the surface of the skin. Sutures that migrate in this way have been known to be the source of additional problems, such as a penile disfigurement from the untidy stitches marks or fibrosis (Fig. 10.5).

It is recommended for skin closure after MC to be done with the most delicate rapidly absorbable sutures. As the inner foreskin of newborns and infants is fragile,



FIG. 10.30 A case of small stitch sinus in the preputial remnant.

6/0 or 7/0 quickly absorbable materials such as polyglactin or polyglecaprone can be used. For older kids and adults, 5/0 quickly absorbable materials may be used. Using medical cyanoacrylate is a good alternative to stitching. It avoids permanent suture marks and suture tunnels that may be problematic. Meticulous haemostasis is vital before cyanoacrylate application. Subcuticular (separate or continuous) suturing, which has similar advantages, can also be used by giving some more time and effort.

Thick and slowly absorbable materials cause permanent suture tracts, which are a common sequel, resulting in disfigurement of the MC scar; very rarely small sinuses may be encountered long time after circumcision at the site of nonabsorbable stitches (Fig. 10.30).

A small stitch granuloma with or without smegma collection may also be seen with the stitch remnants (Fig. 10.31).

POST-MALE CIRCUMCISION SMEGMA COLLECTION

Definition: The word smegma is of Greek origin meaning soap or an ointment.

Smegmoma: Preputial smegma cyst.

Smegmaliths: Pieces of hard contaminated and retained smegma.

Smegma has a characteristic slimy odour and is composed of epithelial debris, fat and proteins. It has mixed bacterial flora, including the smegma bacillus (*Mycobacterium smegmatis*) in 50% of man.

Smegma is the natural secretion of the prepuce, like other body secretions, such as earwax. So it is not harmful by itself, unless it is complicated by other pathogens, bacterial colonization, viral overgrowth or a combination of organisms. Smegma collection is usually associated with phimosis and different forms of balanitis or balanoposthitis.

Smegma secretion and distribution had a great variation between individuals and between different ages without a clear explanation. Wright²⁰ states that smegma is produced from minute microscopic protrusions of the mucosal surface of the foreskin and that living cells constantly grow towards the surface, undergo fatty degeneration, separate off and form smegma.

Smegma should be cleaned frequently in uncircumcised boys by the mother during childhood and by the boy himself later on. Circumcised boys, especially those with excess skin remnants, may have a marked smegma

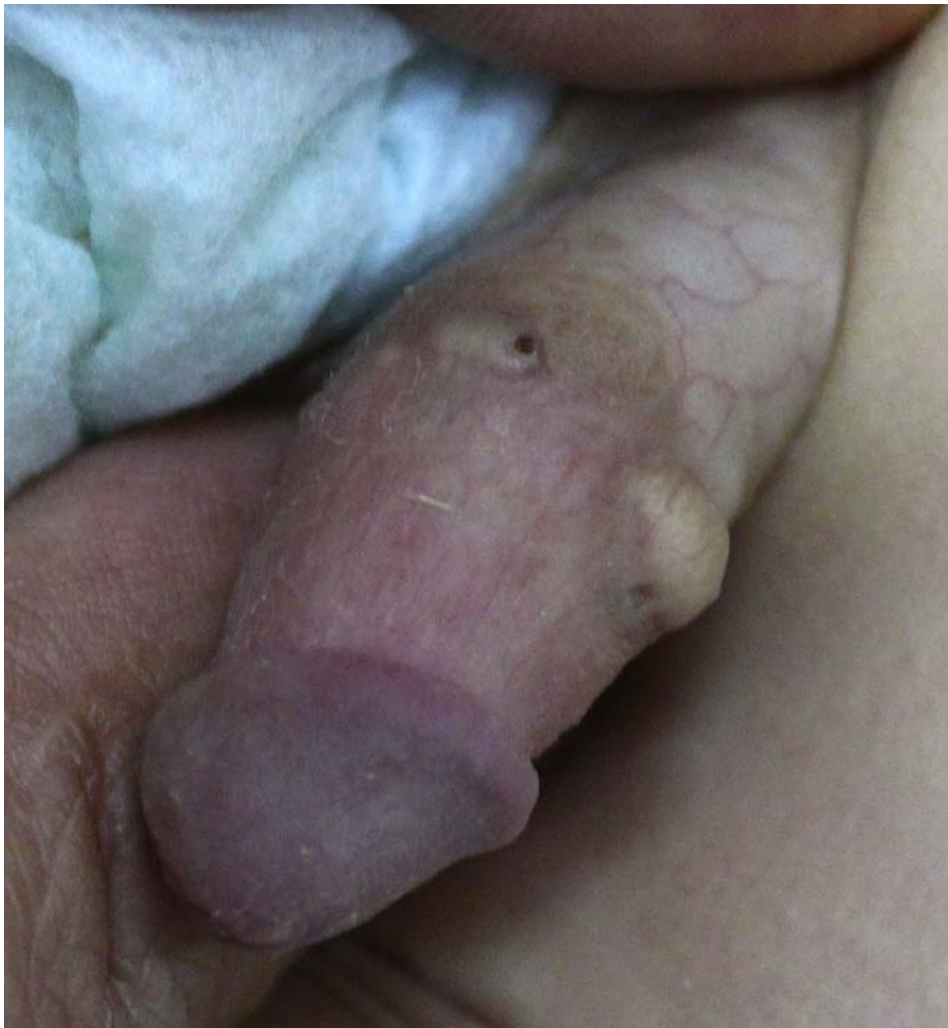

FIG. 10.31 Multiple small collections of granulation tissue around a nonabsorbable stitch, with smegma collection.

secretion and attention should be paid to clean it as in uncircumcised boys (Fig. 10.19).

During circumcision, smegma should be cleaned and removed meticulously with saline wash, otherwise any retained small pieces will be entrapped and will accumulate between the edges of the incised prepuce and result in different forms of cysts of smegma, which may become large and will lead to different complications.

Smegma Cyst

Aggregation of smegma in circumcised children is not rare and may present alone without any other complications or in association with skin bridges (Fig. 10.12) or with stitch granuloma (Fig. 10.31) as a yellowish cystic or doughy swelling of different sizes at the cut edges of the prepuce (Fig. 10.32). Sometimes the swelling may become larger, disfiguring the penis (Fig. 10.33). It is

usually presented as a single swelling, but cases with multiple small cysts are not rare (Fig. 10.34).

Smegma, produced under the foreskin, is made of 27% fat and 13% protein and contributes to the higher occurrence of *Malassezia* fungal species in uncircumcised versus circumcised men (49% vs. 7%). The frequency of yeast colonization in smegma is around 11%.²¹

It is considered as an inclusion cyst, and if seen at the ventral surface of the penis, or along the median raphe, it should be differentiated from other rare true penile cysts, such as parameatal cysts, mucoid cysts or median raphe cysts²² (Fig. 10.35).

These cysts are liable to irritation, traumatic rupture and infection with abscess formation. This complication is avoidable, but once diagnosed, careful excision under general or regional anaesthesia, with meticulous penile skin closure, is indicated and will avoid recurrence.²³

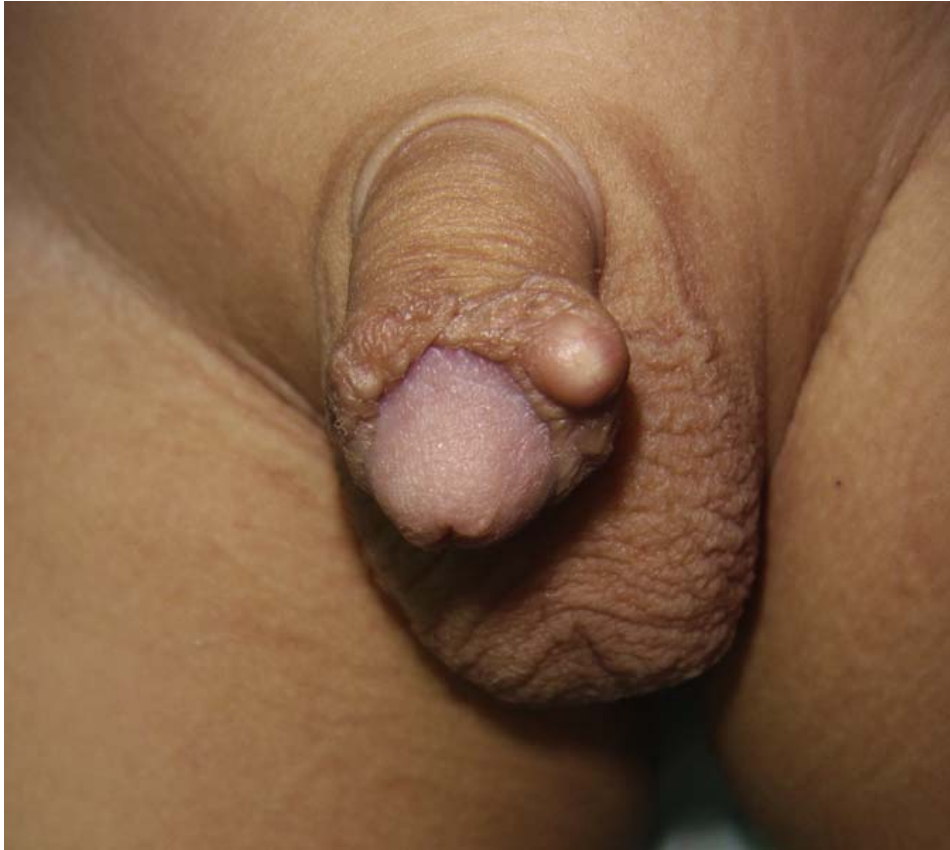

FIG. 10.32 A single small smegma cyst at the rim of a circumcision scar.

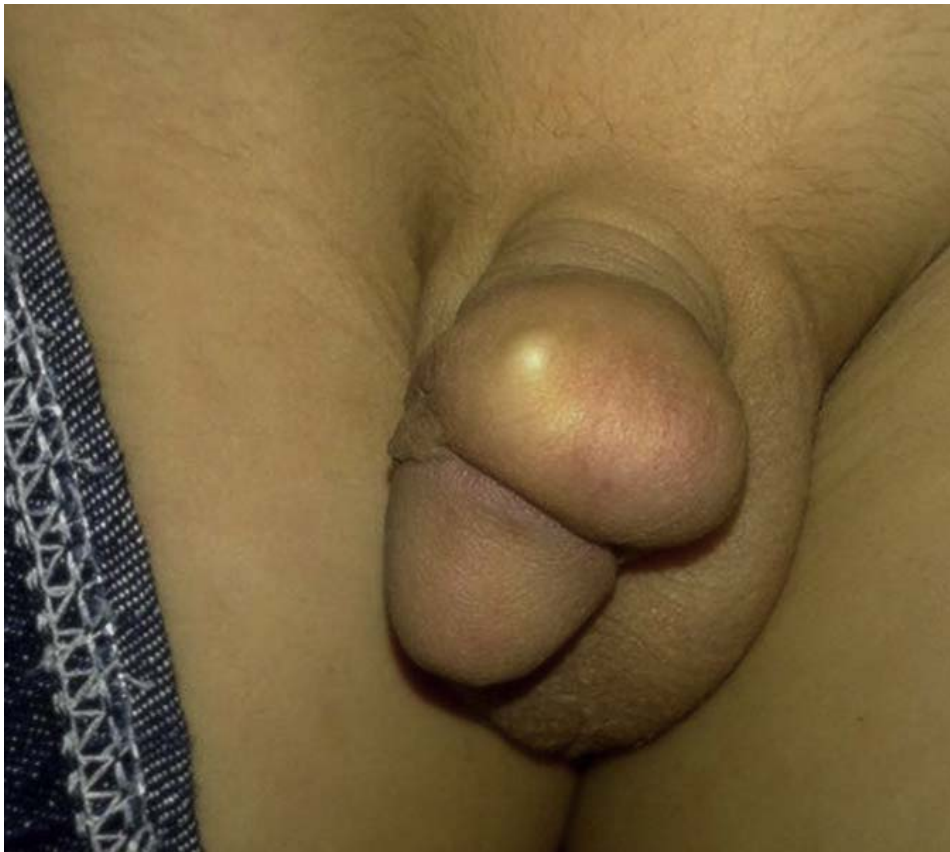

FIG. 10.33 A large smegma cyst at the dorsum of the penis.

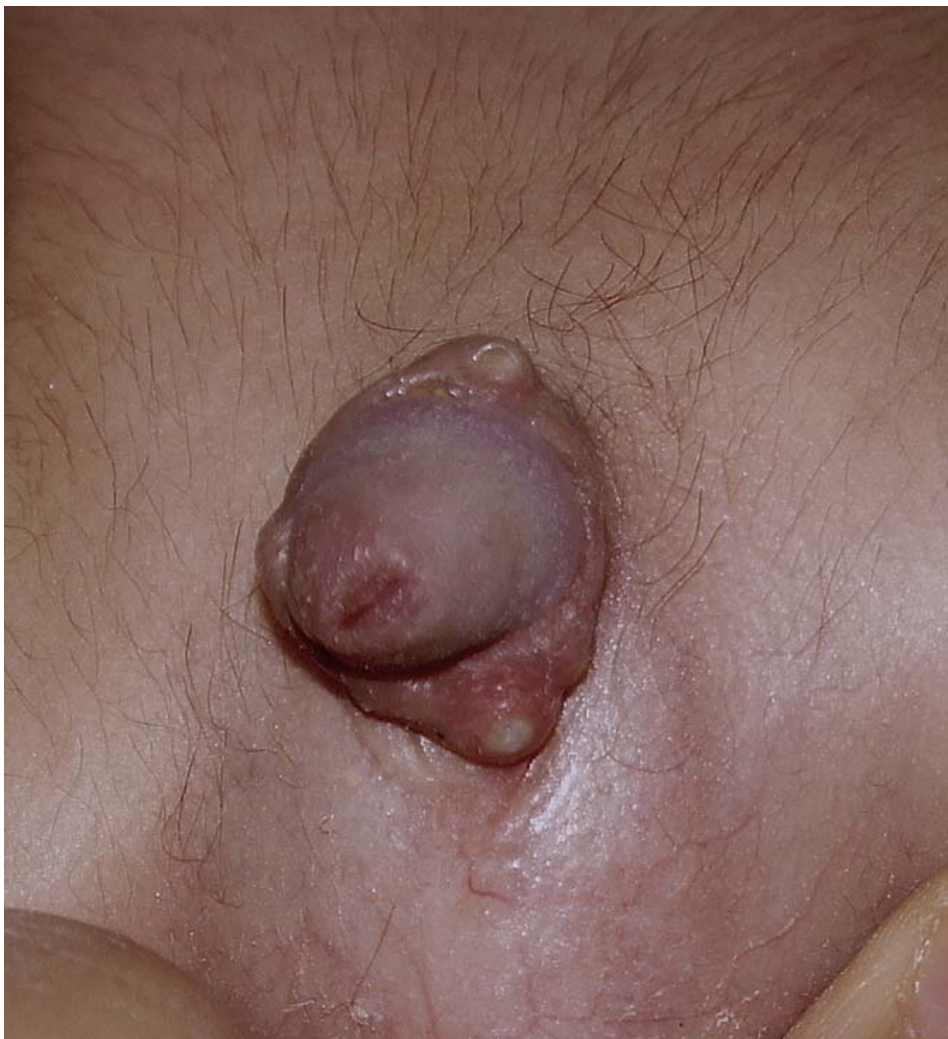

FIG. 10.34 Multiple small smegma cysts.

POST-CIRCUMCISION PENILE LYMPHOEDEMA

Generally, lymphoedema of the external genitalia is an unusual problem in countries where endemic filariasis is rarely experienced. The abnormal retention of lymphatic fluid in subcutaneous tissue as a result of lymphatic obstruction can cause swelling, pain, disfigurement, difficulties in urination and later on a decrease in potency. Lymphoedema may be idiopathic or secondary to inflammation, surgical incision, neoplasm, radiation, hypoproteinemia, venous thrombosis and other medical conditions.

Preputial cutting severs the lymph vessels of the penile skin, and it may interrupt the circulation of lymph and sometimes cause different grades of penile lymphoedema,²⁴ which is a painful, disfiguring

condition in which the remaining skin of the penis swells with trapped lymph fluid. A few cases had been reported in the literature complicating MC, but we diagnosed a few cases with a variable extension and different forms of presentations (Fig. 10.36).

On the other hand, cutaneous lymphangiectasia (CL) or acquired lymphangioma is another lymphatic malformation, mostly congenital, whereas acquired CL occurs because of the obstruction of deeper lymphatic vessels secondary to other causes.²⁵ It is characterized by the presence of a circumscribed eruption of thin-walled, translucent vesicles and ranges from clear, fluid-filled blisters to smooth, flesh-coloured nodules, sometimes with a coexisting lymphoedema. Mostly, CL is asymptomatic but pruritus, burning or painful lesion and sometimes a foul-smelling viscous discharge may also occur. We have only one case diagnosed as

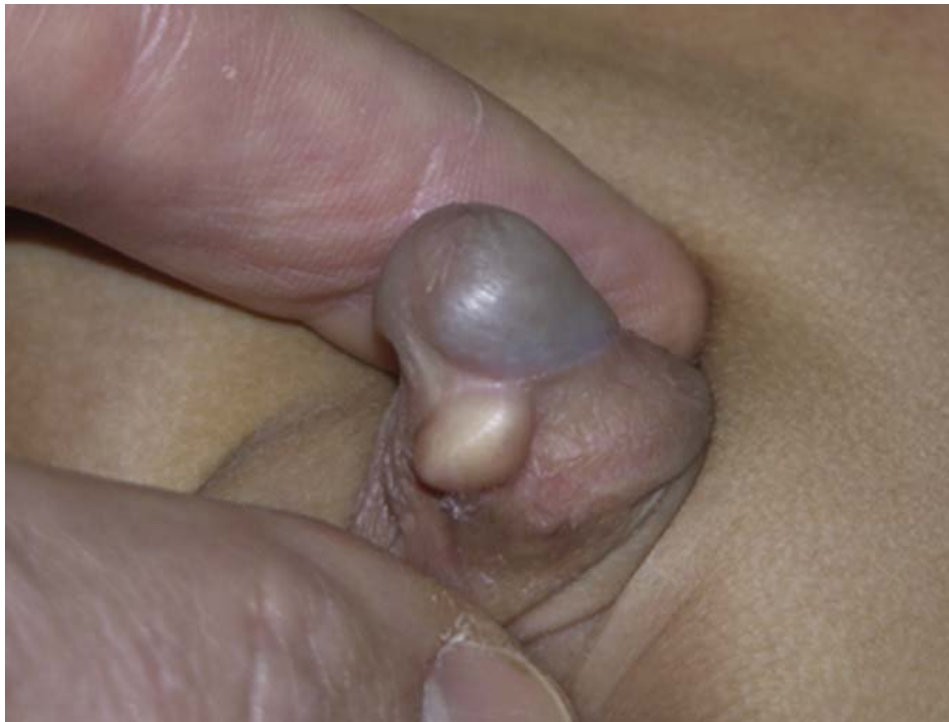

FIG. 10.35 Post-circumcision smegma cyst in the ventral penile surface looks like a mucoid penile cyst.

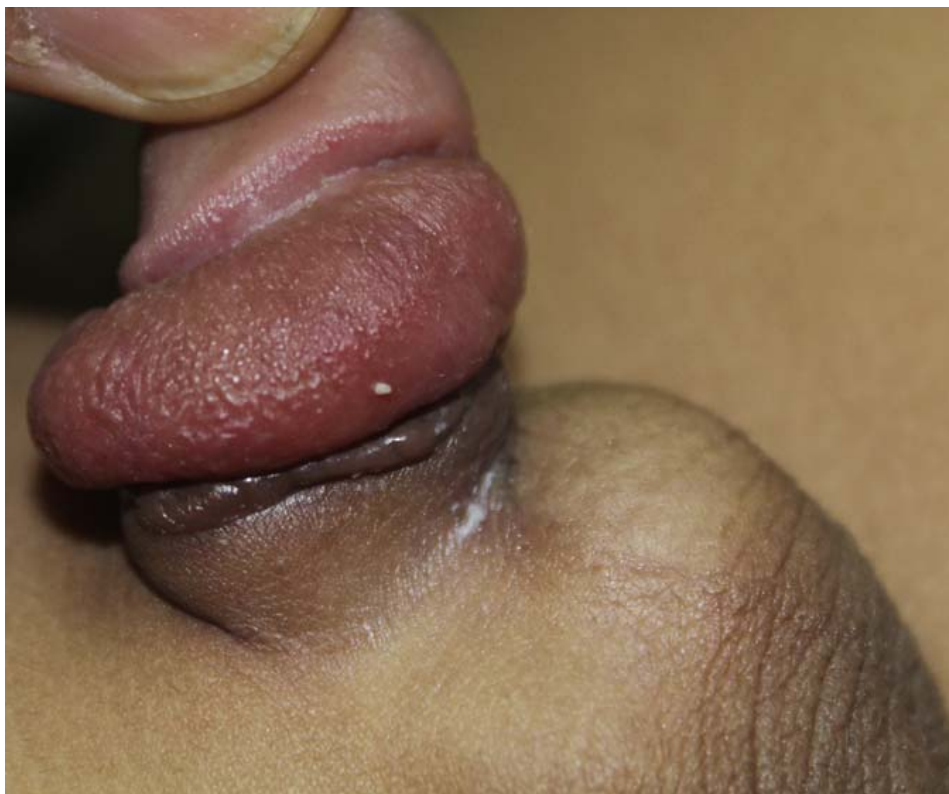

FIG. 10.36 A localized lymphoedema of excess inner prepuce after guillotine male circumcision.

having CL in a previously normal adolescent, who was circumcised at the age of 10 years under general anaesthesia and developed CL at the scar of circumcision 2 months after the procedure, with progressive extension of the characteristic skin lesions in the penile and scrotal skin, which resulted in an ugly scar at the coronal sulcus; histopathologic findings confirmed the diagnosis of CL (Fig. 10.37).

Pathophysiology

There are two lymphatic systems in the penis: the superficial system and the deep system. The superficial system drains the prepuce and the skin of the penis, and it flows into the superomedial zone of the superficial inguinal nodes. The deep system drains the glans, runs beneath the deep fascia and flows both directly into the pelvic nodes and the superficial inguinal nodes. These anatomic structures can explain the discrepancy between the severely involved penile skin and the intact

glans, as observed in Fig. 10.38, where the extensive excision of penile skin during MC results in lymphoedema of the remnant penile and scrotal skin, while the glans is minimally affected (Fig. 10.38).

The lymphatic vessels of the superficial dermal plexus drain a fixed area of skin through the vertical collecting lymphatics to the deep plexus. The damage to deep lymphatic vessels leads to back pressure and dermal backflow, with subsequent dilatation of the upper dermal lymphatics. Because circumferential excision of the penile skin above the deep fascia does not interfere with the deep lymphatic system, secondary penile lymphoedema is unusual.²⁶

Diagnosis

The diagnosis is mainly clinical aided by the histopathologic finding of dilated lymphatics in the dermis during surgical treatment.

Post-MC lymphoedema could be classified according to its extension into

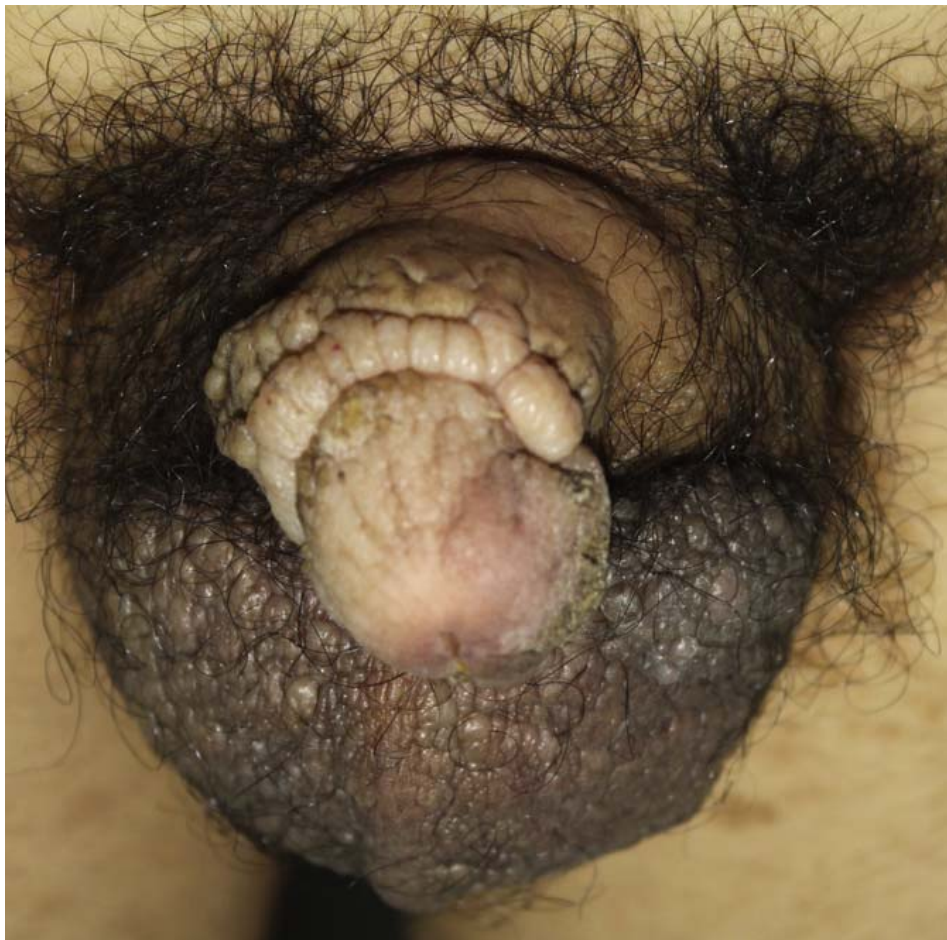


FIG. 10.37 A case of cutaneous lymphangiectasia complicating adult male circumcision, with the main brunt of the lesion at the circumcision scar and with an extension to the scrotal skin.



FIG. 10.38 Extensive excision of the outer prepuce and penile skin results in secondary lymphoedema of the scrotum, with minimal glandular involvement.

- lymphoedema of the excess remnant prepuce (Fig. 10.36),
- penile lymphoedema,
- penoscrotal lymphoedema (Figs. 10.38 and 10.39),
- CL (Fig. 10.37).

Differential Diagnosis

Lymphoedema detected after MC should be differentiated from cases of congenital primary lymphoedema (lymphoedema praecox), which is a rare anomaly and may be present since birth or may develop later but unrecognized before performing MC and only manifested or could be aggravated after the surgical trauma

of MC, as circumcision may have initiated and accelerated the lymphatic obstruction leading to oedema²⁷ (Fig. 10.39).

Post-MC lymphoedema should also be differentiated from cases of angioneurotic oedema, which may accidentally follow MC due to local or systemic causes, such as insect bites or drug eruption, in the latter case, the condition usually affects other organs with itching and responding early to antihistaminic medications²⁸ (Fig. 10.40).

Lymphangiectasia has to be differentiated from herpes genitalis, genital warts and molluscum contagiosum.

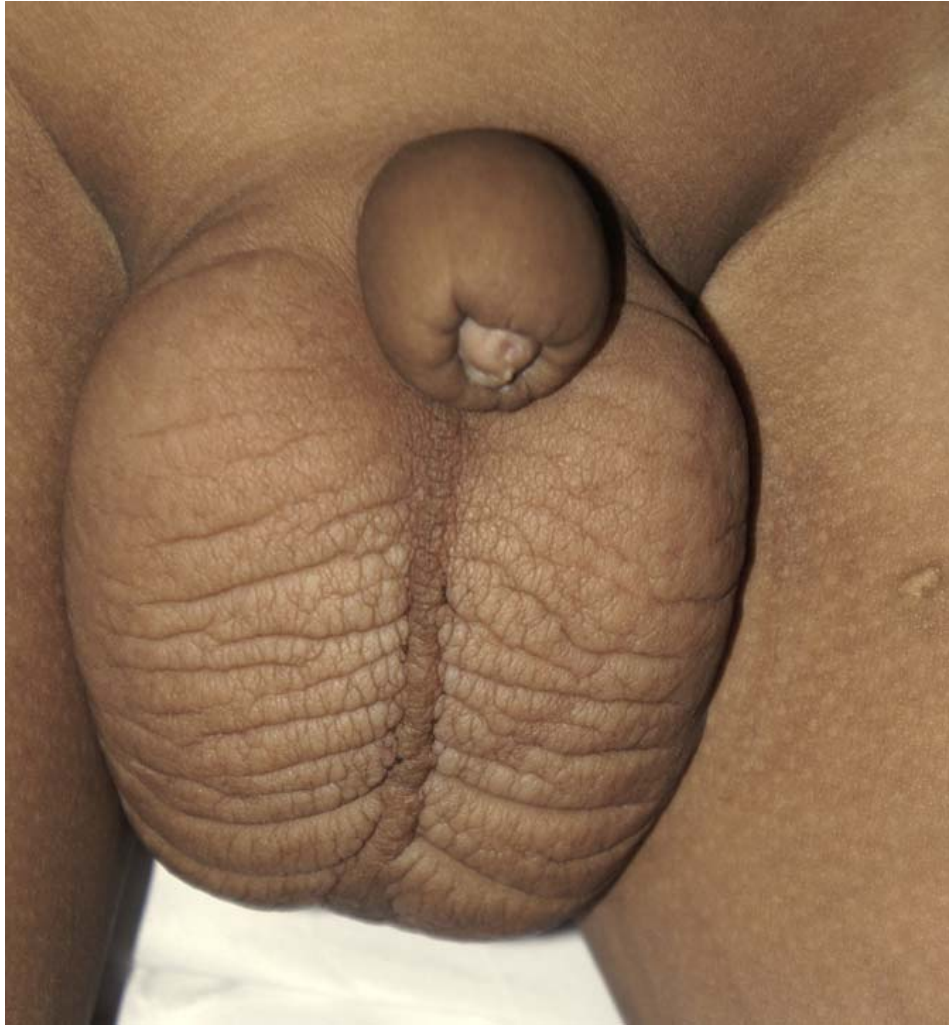

FIG. 10.39 A circumcised child with congenital primary lymphoedema affecting the penile and scrotal skin.

Treatment

Regardless of the cause, lymphoedema is not fatal, but its chronic nature makes the patient miserable. Treatment should be directed towards the cause and aimed for reduction of the underlying oedema and control of infection.

Management of isolated penile lymphoedema is challenging, and medical treatments include the use of oral antibiotics for identified infectious pathogens, empirical antibiotics for presumed subacute

genital infections, oral steroids and topical steroid application limited to areas with cutaneous lesions.²⁹ Although various methods of lymphangioplasty have been described by several authors, they are technically difficult and unreliable and are therefore not often performed. The most common approach is excision of all the involved skin and subcutaneous tissue to the level of Buck fascia followed by coverage of the genitalia with local tissue flaps or skin grafts.³⁰

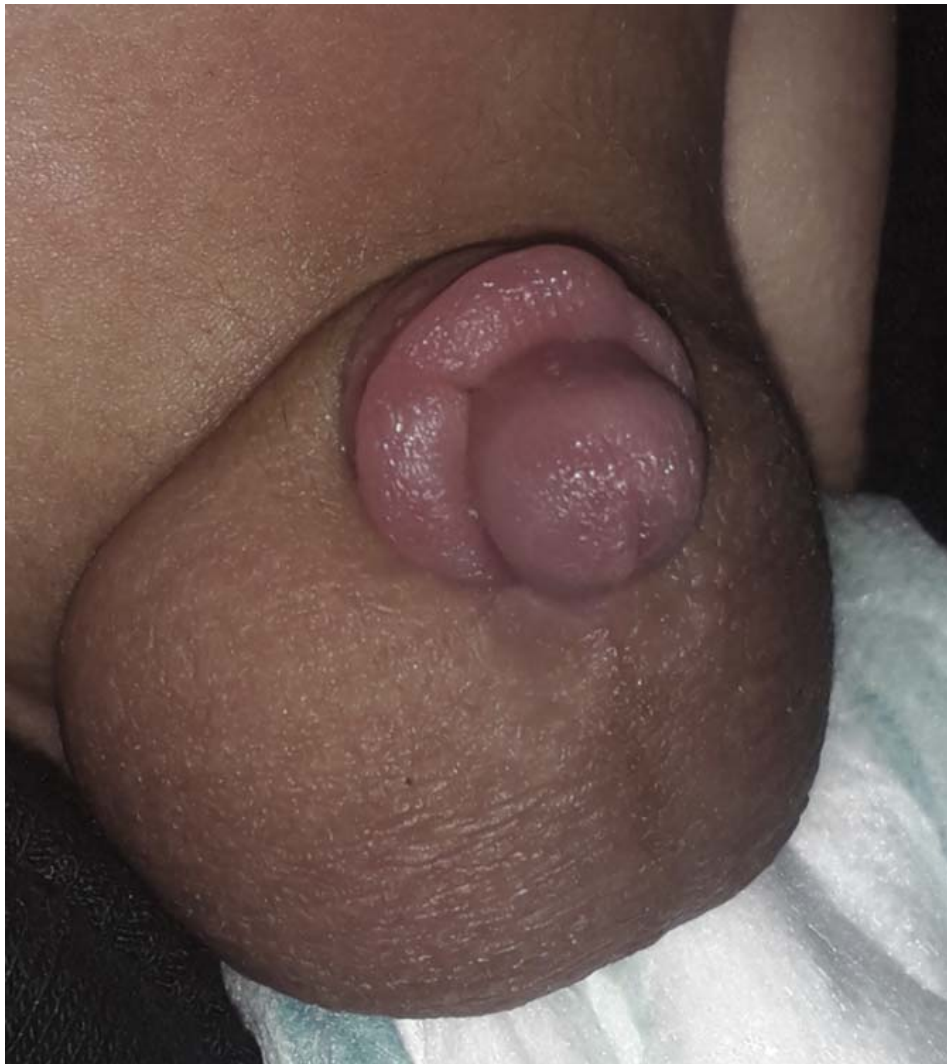

FIG. 10.40 A case of post-male circumcision angioneurotic oedema affecting the preputial remnant and extending to the penile and scrotal skin, which resolved after conservative measures.

REFERENCES

1. Ulman İ, Ali T. How do I get a perfect cosmetic result after circumcision? In: Rané A, et al., eds. *Practical Tips in Urology*. London: Springer-Verlag; 2017. https://doi.org/10.1007/978-1-4471-4348-2_15.
2. Fergusson DM, Lawton JM, Shannon FT. Neonatal circumcision and penile problems: an 8-year longitudinal study. *Pediatrics*. 1988;81:537–541.
3. Akyol I, Soydan H, Kocoglu H, Ates F, Karademir K, Baykal K. A novel tool to predict the cosmetic outcome after circumcision: penile visibility index. *Int J Clin Med*. 2014;5:605–610. <https://doi.org/10.4236/ijcm.2014.510082>.
4. Pieretti RV, Goldstein AM, Pieretti-Vanmarcke R. Late complications of newborn circumcision: a common and avoidable problem. *Pediatr Surg Int*. 2010;26(5):515–518.
5. Krill AJ, Palmer LS, Palmer JS. Complications of circumcision. *Sci World J*. 2011;11:11. <https://doi.org/10.1100/2011/373829>. Article ID 373829.
6. Draaijers LJ, Tempelman FR, Botman YA, et al. The patient and observer scar assessment scale: a reliable and feasible tool for scar evaluation. *Plast Reconstr Surg*. 2004;113(7):1960–1965.
7. Maizels M, Zaontz M, Donovan J. Surgical correction of the buried penis: description of a classification system and a technique to correct the disorder. *J Urol*. 1986;136:268–271.
8. Williams CP, Richardson BG, Bukowski TP. Importance of identifying the inconspicuous penis: prevention of circumcision complications. *Urology*. 2000;56:140–143. [https://doi.org/10.1016/S0090-4295\(00\)00601-4](https://doi.org/10.1016/S0090-4295(00)00601-4).
9. Borsellino A, Spagnoli A, Vallasciani S, Martini L, Ferro F. Surgical approach to concealed penis: technical refinements

- and outcome. *Urology*. 2007;69:1195–1198. <https://doi.org/10.1016/j.urology.2007.01.065>.
10. Van Howe RS. Variability in penile appearance and penile findings: a prospective study. *Br J Urol*. 1997;80:776–782.
 11. Blalock HJ, et al. Outpatient management of phimosis following newborn circumcision. *J Urol*. 169(6): 2332 – 2334.
 12. Skrodzka M, et al. How to do a circumcision, when the foreskin is welded to the glans. *J Sexual Med*. 15(7): S179 – S180.
 13. Bragg BN, Leslie SW. *Paraphimosis* NCBI Bookshelf. A Service of the National Library of Medicine, National Institutes of Health. StatPearls [Internet]. Treasure Island (FL): StatPearls Publishing; June 2017. Bookshelf ID: NBK459233 PMID: 29083645.
 14. Talini C, Antunes LA, de Carvalho BCN, et al. Circumcision: postoperative complications that required reoperation. *Einstein*. 2018;16(3):eAO4241. <https://doi.org/10.1590/S1679-45082018AO4241>.
 15. Palmisano F, Gadda F, Spinelli MG, Montanari E. Glans penis necrosis following paraphimosis: a rare case with brief literature review. *Urol Case Rep*. 2018;16:57–58. <https://doi.org/10.1016/j.eucr.2017.09.016>.
 16. Hayashi Y, Kojima Y, Mizuno K, Kohri K. Prepuce: phimosis, paraphimosis, and circumcision. *Scientific World J*. 2011;11:289–301. <https://doi.org/10.1100/tsw.2011.31>.
 17. Warwick DJ, Dickson WA. Keloid of the penis after circumcision. *Postgrad Med*. 1993;69(809):236–237.
 18. Yong M, Afshar K, MacNeily A, Arneja JS. Management of pediatric penile keloid. *Can Urol Assoc J*. 2013;7(9–10): E618–E620. <https://doi.org/10.5489/cuaj.408>.
 19. Hypertrophic scar and keloid formation after male circumcision - a case report. *Eur J Plast Surg*. 2009; 32(4):213–215. <https://doi.org/10.1007/s00238-008-0319-y>.
 20. Wright J. How smegma serves the penis. *Sexology*. 1970;37: 50–53.
 21. Aridogan IA, Ilkit M, Izol V, Ates A, Demirhindi H. Glans penis and prepuce colonisation of yeast fungi in a paediatric population: pre- and post circumcision results. *Mycoses*. 2009;52(1):49–52.
 22. Baky FMA. The spectrum of genital median raphe anomalies among infants undergoing ritual circumcision. *J Pediatr Urol*. 2013;9:e872–e877. <https://doi.org/10.1016/j.jpuro.2012.11.018>.
 23. Fahmy M: Smegma in Congenital Anomalies of the Penis, Illustrative Textbook. Springer International Publishing, Pages 237–240. ISBN 978-3-319-43310-3
 24. Shulman J, Ben-Hur N, Neuman Z. Surgical complications of circumcision. *Am J Dis Child*. 1964;107:149–154. <https://doi.org/10.1001/archpedi.1964.02080060151007>.
 25. Arya S, Nyati A, Moti, Lal B. Cutaneous lymphangiectasia of genitalia: a rare occurrence. *J Assoc Phys India*. 2018; (66):94.
 26. Dewire D, Lepor H. Anatomic considerations of the penis and its lymphatic drainage. *Urol Clin*. 1992;19:211–219.
 27. Serkan Y, Gaye T, Tayfun A. Circumcision as an unusual cause of penile lymphedema. *Ann Plast Surg*. 2003;50(6): 665–666. Letters.
 28. Fahmy M. Penile lymphedema. In: *Congenital Anomalies of the Penis*. Cham: Springer; 2017. https://doi.org/10.1007/978-3-319-43310-3_18.
 29. Garaffa G, Christopher N, Ralph DJ. The management of genital lymphoedema. *BJU Int*. 2008;102:480–484. <https://doi.org/10.1111/j.1464-410X.2008.07559.x>.
 30. Modolin M, Mitre AI, da Silva JC, et al. Surgical treatment of lymphedema of the penis and scrotum. *Clinics*. 2006;61: 289–294.

Circumcision Scars and Aesthetic Concerns

JONATHAN A. ALLAN, PhD

ABSTRACT

In North America, it is fairly common to imagine the uncircumcised, or the intact, penis as 'ugly'. Numerous examples can be found in popular cultures that refer to the uncircumcised penis and its foreskin as abject, disgusting, dirty, etc. As such, the circumcised penis has become something of a norm in North America, especially the United States where in the words of one scholar, 'circumcision is consistent with American notions of good parenting'. Likewise, the foreskin has seemingly disappeared from medical textbooks, as noted by J.R. Taylor, A.P. Lockwood and A.J. Taylor: 'The current tendency to eliminate the prepuce from anatomy textbooks reflects the popular emphasis on the glans; perhaps the wrinkling and pleating of the retracted prepuce, like unwanted hair, is an affront to good taste or simply superfluous to requirements.' What all this assumes, of course, is that the circumcised men are aesthetically superior and that all circumcisions will necessarily result in this aesthetic improvement – in this logic, then, there are never any mistakes or accidents. However, as has been well documented, circumcision complications do arise, and sometimes they leave the penis with scars, which can become an aesthetic concern; indeed, the correction, as it were, can become a new problem. This chapter thus considers the (possible) ugliness of the circumcised penis.

KEYWORDS

Aesthetics; Circumcision; Foreskin; Scars.

In North America, it is fairly common to imagine that the uncircumcised penis is 'ugly'.¹ Numerous examples can be found in popular cultures that refer to the uncircumcised penis and its foreskin as abject, disgusting and dirty. As such, the circumcised penis has become something of a norm in North America, especially in the United States where 'circumcision is consistent with

the American notions of good parenting'.² Indeed, as noted by J.R. Taylor, A.P. Lockwood and A.J. Taylor, the foreskin has disappeared from medical textbooks:

*The current tendency to eliminate the prepuce from anatomy textbooks reflects the popular emphasis on the glans; perhaps the wrinkling and pleating of the retracted prepuce, like unwanted hair, is an affront to good taste or simply superfluous to requirements.*³

What all this assumes, of course, is that the circumcised penis is aesthetically superior and that all circumcisions will necessarily result in this same aesthetic improvement – in this logic, then, there are never any mistakes or accidents. However, as has been well documented, circumcision complications do arise, and sometimes they leave the penis with scars, which can become an aesthetic concern; indeed, the correction, as it were, can become a new problem. This chapter thus considers the ugliness of the circumcised penis, especially when complications arise.

A NOTE ON TERMINOLOGY

I use the term 'uncircumcised' to refer to the penis that has not been circumcised. I recognize, however, that this terminology is problematic for some, especially those in the anti-circumcision community. Wallace⁴ has proposed that we ought to use three distinct terms to refer to different types of penises: 'intact (those in the natural state), *circumcised* (those with the prepuce removed), and *uncircumcised* (those with a restored prepuce or pseudo-prepuce).' I recognize that for Wallace these distinctions are important, and he is not alone. In one article published in the Australian Forum, a man explains, 'I really resent the calling of a man who has a natural penis with foreskin ... 'uncircumcised' as if it was something that had to be done!'⁵ Likewise, Lander⁶ explains that using the term 'uncircumcised' is 'irrational' because it requires that one 'define the normal as "not operated upon"' and thus argues that 'the normal male should be addressed as such, or referred to as

"intact". However, it seems to me that 'uncircumcised' is the commonly accepted terminology for a penis that has retained its foreskin, even if there are a growing number of men who would prefer a term such as 'intact' or 'natural'. Moreover, what is missing from Wallace's typologies is the case of *aposthia*, in which, the neonate is born without a foreskin. Regardless, what should be clear is that the profession should respect the term or terms that an individual uses for himself.

A NOTE ON APPROACH

This article is established in the social sciences and humanities, rather than the medical sciences; however, I believe it contributes to both disciplines and fields of inquiry and practice. Just as I have done in my research on the uncircumcised penis, I draw on a range of sources that may be unfamiliar to those trained in the medical sciences, or even sources that might never be quoted in the medical sciences, for any number of reasons. As a scholar, I am as likely to work with an ethnographic study as I am to work with a sex advice column in a popular magazine. I think it is important that wherever we come from that we are engaging with a wide range of materials because we likely will encounter a wide range of perspectives in the people we engage with, the audiences with whom we speak and the patients who are cared for by the medical profession.

CIRCUMCISION

Circumcision is perhaps the world's first surgery, and most would likely agree that it is, at the very least, probably one of the oldest of all surgical procedures.⁷ Incidentally, decircumcision, or foreskin restoration, is likely the oldest, and thus, the first aesthetic surgery as Gilman has argued.⁸ Hutson⁹ notes, 'circumcision has a long history in ancient societies of the Middle East, and is likely to have arisen as an early public health measure for preventing recurrent balanitis, caused by sand accumulating under the foreskin.' Of course, circumcision has also been 'a major part of the ritual for such religions as Judaism, Christianity and Islam', and as Hutson noted, 'it is probably not accident that all of these arose in the Middle East.'⁹ Today, circumcision is carried out not only for religious reasons but also, and importantly, for secular reasons, such as 'the father's desire for the baby to look like himself'⁹ which is one of the most common reasons, as well as a fear of the locker room, wherein a boy would have a penis that looks different from that of those around him. For example, a 1987 article found that the most popular reason (46%) for circumcision 'was wanting our son to resemble other males'.¹⁰ Likewise, a 2014 study

published in the *Pediatric Surgery International* found that little has changed. In this study, we learn that the most common reasons for circumcision were 'to be like dad' (69%) and social acceptance among peers (69%), and the other reasons included health and in only 11% of cases were religious reasons given for routine neonatal circumcision in the hospital setting.¹¹ Indeed, in a 2015 study published in *The Journal of Perinatal Education*, the reasons for circumcision remain similar: '[P]arents choose circumcision for their newborn sons for the child to have the same appearance as his father, to reduce his risk for infection, and because of beliefs about hygiene.'¹² At bottom, then, it must be admitted that 'a man's perception of his genitalia has a significant effect on self-esteem and sexual identity,'¹³ which is why it is important that clinicians consider the question of aesthetics with regard to circumcision decisions.

CIRCUMCISION RISKS AND AESTHETIC CONSIDERATIONS

Given that 'circumcision is the most frequently performed operation in the world,'¹⁴ in addition to the influence on 'self-esteem and sexual identity,'¹³ it seems valuable and important to consider the impact of the operation. From the outset, it should be recalled that the overall complication rate of 1.5% is low; however, as Schröder notes, "given the number of circumcisions performed worldwide, the number of affected children is enormous."

In a survey completed by the National Organization to Halt the Abuse and Routine Mutilation of Males, respondents reported wide-ranging physical consequences from their circumcisions. Among the most significant consequences were prominent scarring (33%), insufficient penile skin for a comfortable erection (27%), erectile curvature from uneven skin loss (16%), pain and bleeding upon erection/manipulation (17%), painful skin bridges (12%) and others, e.g. beveling deformities of the glans, meatal stenosis and recurrent nonspecific urethritis (20%).¹⁵

Admittedly, this data is likely biased insofar as the study was conducted by an organization that has the explicit mandate of putting an end to routine neonatal circumcision. But what is valuable in this list is a series of reasons, commonly presented, against circumcision. Then the risks of circumcision are prominent scarring, insufficient penile skin for a comfortable erection and erectile curvature. Some of these reasons are more physical than aesthetic, but it is difficult to distinguish between the two, especially for a man in whom his penis has provided challenges to his self-esteem and sexual identity.¹³

When we think about circumcision complications, we ought to move beyond the merely functional ‘does the penis still work?’ and towards other adjacent or orthogonal considerations, for instance, aesthetics. I argue, it would be advantageous to begin to think through the aesthetics of circumcision, especially given how frequent the reasons for circumcision are, in one sense or another, aesthetic, for instance, the circumcised penis looks better than the uncircumcised penis or for a son to look like his father and/or brothers. Although the latter reason may speak to community, it is also an aesthetic argument, which is to say, about appearances.

SCARS

Circumcisions, as we likely know, are not uniform; that is, not all circumcised penises look the same, even though they will look similar. There are different methods for circumcision, which will produce different results, at least aesthetically speaking. Gérard Zwang, for instance, notes that ‘the scar created by ritual circumcision, practiced in a workmanlike manner by non-doctors—be they mohels or barbers—is usually unsightly, torturous, and irregular, especially if it has suppurated.’¹⁶ Zwang’s concern is ritual circumcision, but many of these same thoughts appear in critiques of medical circumcision. Nonetheless, what remains true is that circumcision does affect the aesthetics of the penis – even arguments for circumcision are often about improving upon the apparent ugliness of the uncircumcised penis.

In the cases of medical circumcisions, there are a few methods that have become commonplace, namely, the Mogen clamp, the Gomco clamp and the Plastibell, as well as less common modes such as the Sheldon clamp, which produces a guillotine-type circumcision.¹⁷ Given these different tools, it stands to reason that

circumcision will not be uniform. Likewise, it has been observed that although the ‘many techniques of circumcision have a common goal: to remove equal amounts of inner and outer epithelial preputial tissue in a rapid, minimally traumatic and haemostatic fashion’, it must be admitted that there is a ‘fairly high [complication] rate (1.5 to 15%), [which] reflects the fact that the procedure is often performed by an inexperienced individual without attention to basic surgical principles.’¹⁷ Incidentally, the Canadian newspaper, *The Globe and Mail*, reported that ‘few, if any, jurisdiction in Canada require physicians to undergo formal training before performing circumcision.’¹⁸

Needless to say, given these dynamics, it is not surprising that circumcision results vary and complications do happen. The circumcision scar may appear in different places along the penis; for instance, one survey noted that one respondent had the scar close behind the glans, whereas the other’s scar was 25 mm back from it (Fig. 11.1).¹⁹

Additionally, although it is true that ‘the Gomco clamp and the Plastibell devices produce an even circular cut’, it must also be acknowledged that ‘if applied crookedly can result in cosmetic problems.’²⁰ Research has shown that the Gomco clamp has an overall complication rate of 1.9% and that the Plastibell’s overall complication rate range from 2.4% to 5%.²¹ In what follows, I focus on a few of these cosmetic problems, specifically missing frenulum, skin bridges or adhesions, two-toned and pigmentation variation and damage to the glans penis.

Missing Frenulum

A *frenulum* is ‘a small fold of integument or mucous membrane that limits the move of an organ or part’, and in the case of the penis, ‘the frenulum tethers the

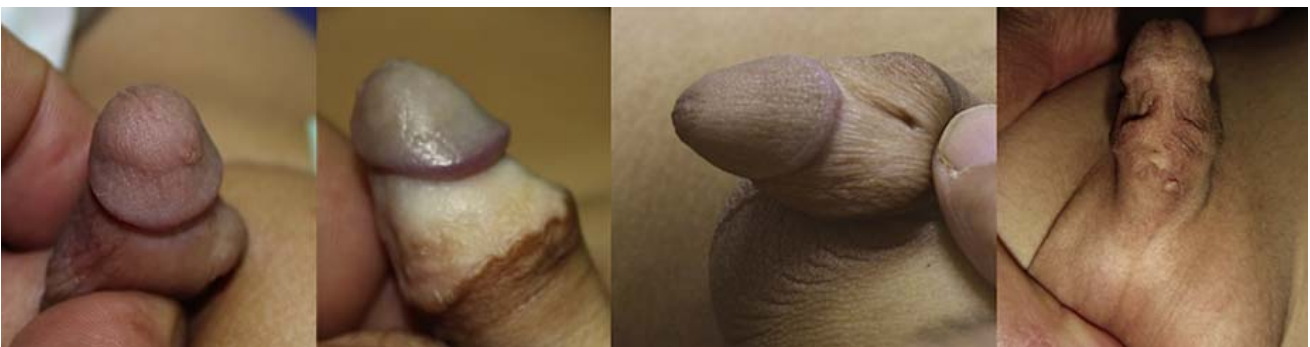

FIG. 11.1 Sequence of post circumcision scars from distal to proximal. From right to left: a scarred glans penis, scarring of the excess inner prepuce, a visible stitch sinus in excess prepuce, and distal scarring in the penile shaft. (Photo credit: Mohamed Fahmy.)

foreskin and brings it back into position following retraction. The frenulum is continuous with the ridged band, which is a highly innervated pleated tissue just inside the opening of the foreskin. The frenulum and ridged band may have the highest concentration of fine-touch and other specialized neuroreceptors in the male body.²² (Figs. 11.2 and 11.3).

As such, the frenulum is often described as the king of all sensitive areas²³ or as the so-called 'G-spot' of males,²⁴ which is why it so often appears in sex advice columns in magazines and sex manuals. More specifically, 'the frenulum is, by design, a little on the short side, so that during an erection and the swelling of the glans there is a pull on the band.'²³ Although not

necessarily an aesthetic concern, for many, it is most certainly a sexual and erotic concern.

Importantly, the frenulum is not removed during all circumcisions, as O'Hara and O'Hara note, 'the tip of the foreskin, and *some or all of the frenulum*, are routinely removed as part of circumcision.'²⁵ Likewise, Hammond and Carmack note that 'the highly erogenous frenulum, often preserved in adult circumcision, is frequently ablated in neonatal circumcision due to the smaller size of the undeveloped penis.'²⁶ Neonatal circumcision, thus, presents an interesting aspect to the ongoing debates about circumcision. It would seem that more care is taken with the adult penis, if we accept the claims of Hammond and Carmack, which

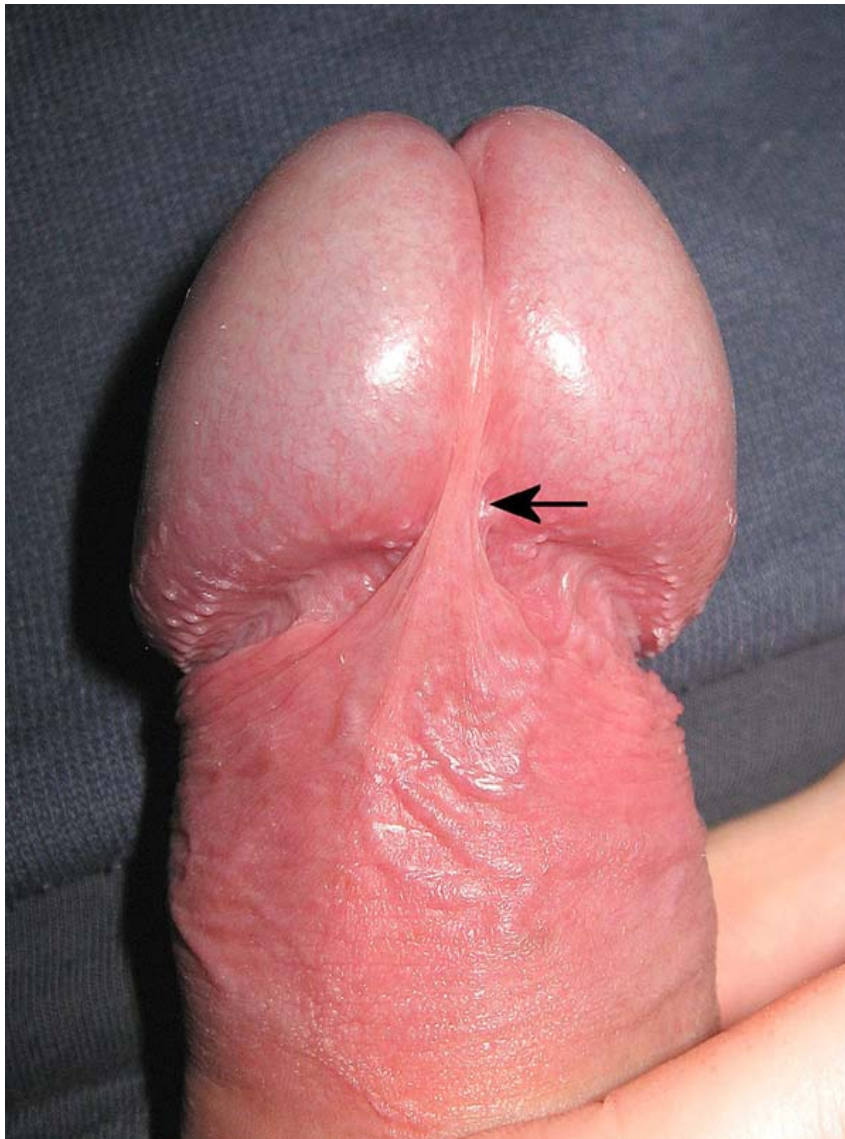

FIG. 11.2 Intact frenulum. (Source: https://upload.wikimedia.org/wikipedia/commons/5/54/Image_of_frenulum.jpg)

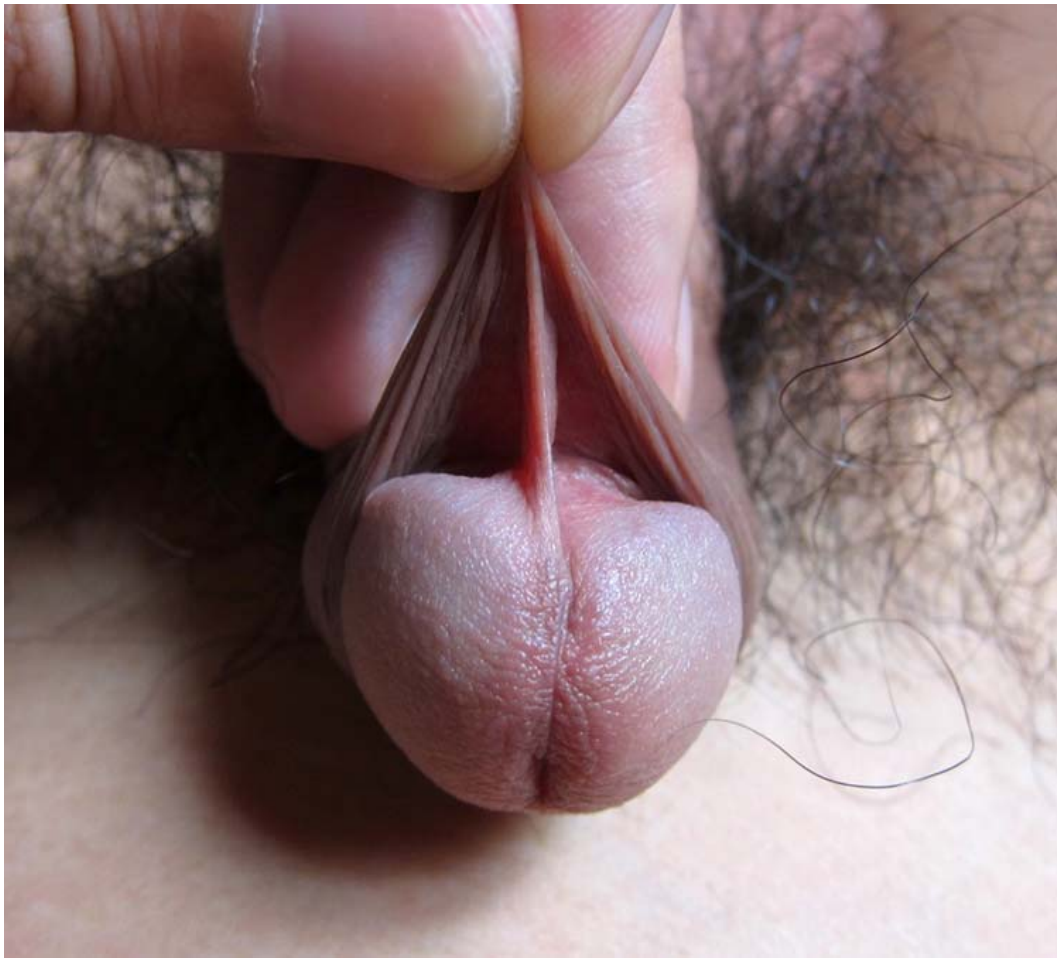

FIG. 11.3 Stretched frenulum with intact prepuce. (Source: https://upload.wikimedia.org/wikipedia/commons/0/02/BPXD_dicksoft_stress.JPG)

undoubtedly has an effect and influence on self-esteem, aesthetics and sexuality.

Skin Bridges

Ponsky and colleagues^{27,28} noted, 'penile adhesions are common after circumcision' and found that 28% of the boys they evaluated had some kind of penile adhesion, including skin bridges. Of the '254 boys 25 were referred for evaluation of penile adhesions, skin bridges, or other circumcision related issues.'²⁸ Gerharz and Haarman²⁹ note that one 'adverse result of circumcision is the formation of cutaneous bridges between the glans penis and the penile shaft' and explain that 'prominent skin bridges are aesthetically disturbing and may lead to tethering of the erect penis, with pain or penile curvature.'

In Fig. 11.4, the skin bridge is relatively minor and is mostly visible because of the erect state. However, the

skin bridge may create discomfort to and/or curvature of the penis. The skin bridge thus shows a deviation from the norm of a circumcised penis or an ideal circumcised penis. Romberg³⁰ explains that a skin bridge 'is a complication in healing of the wound, by which a piece of skin from the shaft of the penis has become attached to the glans, or another point along the shaft, forming a "bridge" that must be surgically corrected.'

Two-Toned and Pigmentation Variations

One additional aesthetic concern, for some men, is what might be understood as a 'two-toned' penis, wherein the penis has two distinct colours, often divided by the circumcision scar (Figs. 11.5–11.7).

This two-toned penis may not be an ideal one, and it may be considered an ugly or aesthetic concern for some men. In a survey completed by National

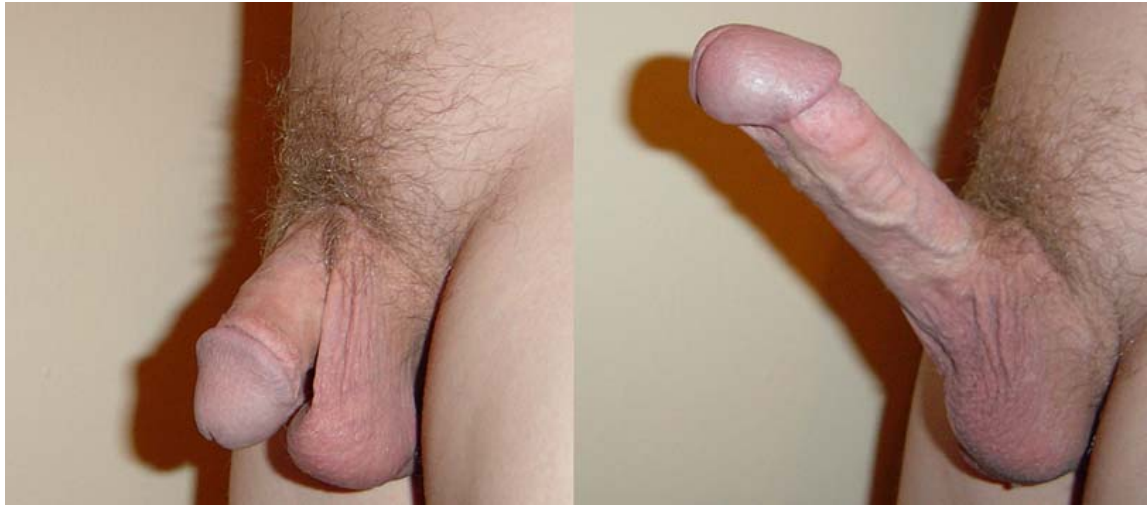

FIG. 11.4 Post circumcision small skin bridge, visible in erect penis. (Source: <https://upload.wikimedia.org/wikipedia/commons/4/4b/Flaccid-erect.jpg>)



FIG. 11.5 Toned pigmentation and visible scar in flacid penis. (Source: https://upload.wikimedia.org/wikipedia/commons/0/06/Circumcised_flaccid.jpg)



FIG. 11.6 Toned pigmentation and visible scar on erected penis. (Source: https://commons.wikimedia.org/wiki/Category:Circumcised_human_penis#/media/File:Circumcised_Penis_2.jpg)

Organization of Restoring Men, UK, 74% of the respondents were dissatisfied with the appearance of their circumcised penises, and particularly, 26% complained about the variation in skin colour.³¹ In the cases shown in Figs. 11.5–11.7, the penis is clearly functional; indeed, in Fig. 11.7, an erect penis is presented (with the frenulum intact). In each case, the circumcision scar is clearly visible. This scar, although likely not of concern for many, is certainly a concern for some; one respondent in a survey explained, ‘the physical scar is hideous, but the emotional scar equates to rape’.³² We should not be quick to dismiss these attitudes or ideas because for these men, they are genuinely held beliefs.

The Glans

Perhaps one of the most extreme examples of scarring and aesthetic concerns would be the example of the amputation of the glans penis, which is recognized as a rare circumcision complication.³³ One case study notes that ‘the Sheldon clamp was placed over the prepuce, and the foreskin was pulled through the clamp and crushed. A scalpel was used to excise the prepuce. It was immediately recognized that the distal third of the penile glans had been surgically amputated.’¹⁷ Another study notes a similar result in six cases that used the Mogen clamp. The Sheldon and Mogen clamps, unlike the Plastibell or the Gomco clamp, do not have a glans protective mechanism that minimizes its inclusion and injury during circumcision.³⁴

In their work, Salle and colleagues observed that Glans amputation during neonatal circumcision is a potentially devastating complication that appears to be particularly associated with the use of the Mogen clamp. They proposed that glans amputation can be prevented by careful preparation of the foreskin with complete lysis of ventral preputial adhesions before the placement of the clamp in order to avoid traction and inadvertent entrapment.³⁵

To be certain, complications do not arise with the Mogen or Sheldon clamp alone. One case study speaks of a child (4 years) who ‘had had a Plastibell circumcision 10 days previously’ and that ‘he had rested his penis on the toilet bowl, when a large wooden seat fell on the glans where the Plastibell ring was. This resulted in traumatic amputation of the glans.’³⁶ In such cases, then, undoubtedly, aesthetic considerations will remain and will need to be attended to. There will be scars from the reattachment of the glans (if possible), or there will be a noticeable absence of a part of the glans.

CONCLUSION: AESTHETICS MATTER

While the measure of a good circumcision might well be functionality, it is important that we take into account the aesthetic concerns. Brennan³⁷ notes that ‘getting “botched” is a persistent anxiety of our augmentation-by-surgery age’, and although the incidence of circumcision complications is minimal, it is not insignificant,



FIG. 11.7 Prominent color change on circumcised penis, with two circumcisions scars following a second circumcisions to correct inadequate foreskin removed after initial circumcisions. The frenulum has been trimmed but retained. (Source: https://commons.wikimedia.org/wiki/Category:Circumcised_human_penis#/media/File:Circumcisedtwice.jpg)

especially with regard to self-esteem and sexual identity,¹³ as well as the perspectives and ideas of others, which, of course, have an influence on self-esteem. There is, of course, a significant body of scholarship that has noted, 'thoughts about one's body, including thoughts specific to one's own genitals, have been linked to men's sexual function.'³⁸ Unsurprisingly, then, 'the role of body image in men's sexual lives

extends also to their penis specifically'; however, 'genital body image has typically focussed on appearance of the penis or penis length.'³⁸ Indeed, as Bossio and Pukall³⁸ note, 'little research has empirically explored the potential role of circumcision status in a man's body appraisal of his body image, particularly as body image relates to sexual functioning.' I certainly agree with Bossio and Pukall, but as this chapter has sought to demonstrate

that not all circumcisions are the same, we need to focus not only on circumcision but also on the quality of circumcision, which includes taking into account aesthetic or cosmetic matters, as well as sexual and functional concerns. As such, circumcision complications should not be treated lightly, even if the penis is functional. We might do well to think about the adjacent concerns: aesthetics, sexuality and self-esteem.

ACKNOWLEDGMENT

This research was undertaken, in part, thanks to funding from the Canada Research Chairs program.

REFERENCES

- Allan JA. The foreskin aesthetic, or ugliness reconsidered. *Men Masculinities*. Online First: <http://journals.sagepub.com/doi/full/10.1177/1097184X17753038>.
- Waldeck SE. Social norm theory and male circumcision: why parents circumcise. *Am J Bioeth*. 2003;3(2):57.
- Taylor JR, Lockwood AP, Taylor AJ. The prepuce: specialized mucosa of the penis and its loss to circumcision. *Br J Urol*. 1996;77:294.
- Wallace WG. An undeniable need for change: the case for redefining human penis types: intact, circumcised, and uncircumcised (all three forms exist and all are different). *Clin Anat*. 2015;28:564.
- James B. Circumcision—what you think. *Australian Forum*. 1989;2(11):12.
- Lander MM. The human prepuce. In: Denniston GC, Milos MF, eds. *Sexual Mutilations: A Human Tragedy*. New York: Plenum Press; 1997:77.
- Gerharz EW, Haarman C. The first cut is the deepest? Medico-legal aspects of male circumcision. *BJU Int*. 2000;86:332.
- Gilman SL. Decircumcision: the first aesthetic surgery. *Mod Jud*. 1997;17(3):201–210.
- Hutson JM. Circumcision: a surgeon's perspective. *J Med Ethics*. 2004;30:238.
- Brod barnemzer J, Conrad P, Tenenbaum S. American circumcision practices and social reality. *Sociol Soc Res*. 1987;71(4):276.
- Freeman JJ, et al. Newborn circumcision outcomes: are parents satisfied with the results? *Pediatr Surg Int*. 2014;30(3):334.
- Mitchell TM, Beal C. Shared decision making for routine infant circumcision: a pilot study. *J Perinat Educ*. 2015;24(3):189.
- Alter GJ, Salgado CJ, Chim H. Aesthetic surgery of the male genitalia. *Semin Plast Surg*. 2011;25(3):189 (Thieme Medical Publishers).
- Schröder A. Circumcision: case against surgery without medical indication. In: Bolnick DA, et al., eds. *Surgical Guide to Circumcision*. London: Springer-Verlag; 2012:188.
- Hammond T. A preliminary poll of men circumcised in infancy or childhood. *BJU Int*. 1999;83(suppl. 1):86.
- Zwang G. Function and erotic consequences of sexual mutilations. In: Denniston GC, Milos MF, eds. *Sexual Mutilations: A Human Tragedy*. New York: Plenum Press; 1997:74.
- Gluckman GR, et al. Newborn penile glans amputation during circumcision and successful reattachment. *J Urol*. 1995;153:778.
- Weeks C. *Canadian Doctors Need More Formal Training in Circumcision*. The Globe and Mail; September 21, 2015. Online: <https://www.theglobeandmail.com/life/health-and-fitness/health/canadian-doctors-need-more-formal-training-in-circumcision/article26454085/>.
- James B. Circumcision—what you think. *Australian Forum*. 1989;2(11):13.
- Romberg R. *Circumcision: The Painful Dilemma*. South Hadley, MA: Bergin and Garvey Publishers; 1985:228.
- Freedman, Lerman, and Bergman. 47–48.
- Van Howe RS. Frenulum. In: Kimmel M, Milrod C, Kennedy A, eds. *The Cultural Encyclopedia of the Penis*. Lanham: Rowman & Littlefield; 2014:75.
- Gralla O. *Happy Down Below: Everything You Want to Know About the Penis and Other Bits*, Trans. Jamie McIntosh. Vancouver: Greystone Books; 2018:39.
- McGrath K. The frenular delta: a new preputial structure. In: Denniston GC, Hodges FM, Milos MF, eds. *Understanding Circumcision: A Multi-Disciplinary Approach to a Multi-Dimensional Problem*. New York: Kluwer Academic/Plenum Publishers; 2001:205.
- O'Hara K, O'Hara J. The effect of male circumcision on the sexual enjoyment of the female partner. *BJU Int*. 1999;83(suppl. 1):80.
- Hammond T, Carmack A. Long-term adverse outcomes from neonatal circumcision reported in a survey of 1,008 men: an overview of health and human rights implications. *Int J Hum Right*. 2017;21(2):194.
- Ponsky LE, Ross JH, Knipper N, Kay R. Penile adhesions after neonatal circumcision. *J Urol*. 2000;164:495.
- Ponsky LE, Ross JH, Knipper N, Kay R. Penile adhesions after neonatal circumcision. *J Urol*. 2000;164:496.
- Gerharz EW, Haarman C. The first cut is the deepest? Medico-legal aspects of male circumcision. *BJU Int*. 2000;86:336–337.
- Romberg R. *Circumcision: The Painful Dilemma*. South Hadley, MA: Bergin and Garvey Publishers; 1985:221.
- Warren JP. NORM UK and the medical case against circumcision. In: Denniston GC, Milos MF, eds. *Sexual Mutilations: A Human Tragedy*. New York: Plenum Press; 1997:95.
- Hammond T, Carmack A. Long-term adverse outcomes from neonatal circumcision reported in a survey of 1,008 men: an overview of health and human rights implications. *Int J Hum Right*. 2017;21(2):200.
- Faydaci G, et al. Amputation of glans penis: a rare circumcision complication and successful management with

- primary anastomosis and hyperbaric oxygen therapy. *Korean J Urol.* 2011;52(2):147.
34. Joao L, Salle P, et al. Glans amputation during routine neonatal circumcision: mechanism of injury and strategy for prevention. *J Pediatr Urol.* 2013;9:765.
35. Joao L, Salle P, et al. Glans amputation during routine neonatal circumcision: mechanism of injury and strategy for prevention. *J Pediatr Urol.* 2013;9:767.
36. Paul C, et al. Surgical repair of traumatic amputation of the glans. *Urology.* 2011;77(6):1472.
37. Brennan J. Porn penis, malformed penis. *Porn Studies.* 2017:6. Online First.
38. Bossio JA, Pukall CF. Attitude toward one's circumcision status is more important than actual circumcision status for men's body image and sexual function. *Arch Sex Behav.* 2018;47:772.

Index

A

AAP. *See* American Academy of Pediatrics (AAP)
Ablatio penis, 163, 167f
Acanthosis, 90
Acquired lymphangioma, 128–130
Acute epididymitis, 18
“Adhesive tape” method, 88
Adolescence
 adolescent circumcision in Africa, 6f
 Ancient Egyptian male circumcision at, 6f
Advanced Tissue Sciences of San Diego, 14
Aesthetic skin edges, 34–35
Africa
 adolescent circumcision in, 6f
 small baby circumcised using razor in, 27f
Akroposthia, 105–107
Al-Tohour (circumcision), 3
Ali’s clamp, 30
American Academy of Pediatrics (AAP), 18, 49–50
Aminoglycoside, 76
Anaesthesia, 177
 and analgesia for MC, 44
 general, 41
 local, 41–42
 regional, 41
 topical, 42
Anaesthesiologists, 41
Analgesia for MC, 44
 apprehensive child undergoing ritual circumcision in rural area, 47f
 milk formula given to baby undergoing circumcision, 46f
Ancient Egyptian male circumcision at adolescence, 6f
Androgen insensitivity syndrome, 52–53
Angioneurotic oedema, 131, 133f
Aposthia, 51, 135–136
Arteries, 65–66
Autonomic innervation, 39

B

Bacterial balanitis, 84, 101–102
Balanitis, 19, 81, 114–116
 risk, 22

Balanitis treatment, 88–89
Balanitis xerotica obliterans (BXO), 84, 88f–89f, 101–102, 105f
Balanoposthitis, 81
Ballooning, 17
Bantu race, 13
Baptism, 17
Basal cells, 90
Biases in studies, 17–19
Bipolar coagulation, 70f
Bleeding
 bleeding-related complications, 50
 complications, 65
 blood supply of penis, 65–68
 classification of post-male circumcision bleeding, 68–69
 control, 34–35
Blood supply of penis
 arteries, 65–66
 magnitude of bleeding complication, 68
 to prepuce, 67
 venous drainage, 66–67
Bone cutting
 clamping, 33–34
 guillotine technique, 36f
Buck fascia, 39
Bulbourethral, 65
Buried penis, 110
BXO. *See* Balanitis xerotica obliterans (BXO)

C

CAA. *See* Circumcision Academy of Australia (CAA)
Canadian Paediatric Society (CPS), 18–19
Candida albicans, 88
Candida balanitis, 87f, 88
Carbon dioxide laser, 34–35
Causative organisms, 74
Caver-nasal, 65
Cavernous nerve (CN), 39, 173
CDC. *See* Centers for Disease Control and Prevention (CDC); US Centers for Disease Control and Prevention (CDC)
Celsus’ first method of “decircumcision”, 180, 180f
Centers for Disease Control and Prevention (CDC), 1, 18, 49–50
Child circumcision, 178

Childhood circumcision. *See* Neonatal circumcision
Children, 41
Chinese Shang Ring, 32
Cicatrical phimosis, 99
Circumcised penis, 135–136
Circumciser, factors relating to, 54–55
Circumcising abnormal baby or deformed penis, 50–53
 adolescent with androgen insensitivity syndrome, 59f
 baby with scrotal transposition circumcised early in infancy, 57f
 circumcised baby with significant buried penis, 57f
 circumcised child with marked genital vascular malformation, 60f
 circumcised during inguinal hernia surgery, 59f
 circumcised micropenis, 61f
 infant with marked right-side hydrocele, 58f
 megameatus intact prepuce, 58f
 neonate with imperforate anus circumcised without recognition, 60f
Circumcision, 49, 65, 135–136
 apparition. *See also* Male circumcision (MC)
 biases in studies, 17–19
 recommendations, 19
 approach, 136
 circumcision, 136
 of concealed penis, 53–54
 baby with apparently concealed penis, 61f
 factors affecting circumcision
 complication rate, 50
 method and technique, 56
 reporting of rate of circumcision complications, 56–62
 scars, 137–141
 and aesthetic concerns, 136–137
 glans, 141
 missing frenulum, 137–139
 sequence of post circumcision scars, 137f
 skin bridges, 139
 two-toned and pigmentation variations, 139–141, 140f–141f
 terminology, 135–136

Note: Page numbers followed by “f” indicate figures.

- Circumcision Academy of Australia (CAA), 18–19
- CL. *See* Cutaneous lymphangiectasia (CL)
- Clamps, 25–26
- Clavien-Dindo classification, 3
- Clindamycin, 76
- Clitoridectomy. *See* Female circumcision
- CN. *See* Cavernous nerve (CN)
- Coagulopathy, 50
- Complications in MC, 3
 - circumcising abnormal baby or deformed penis, 50–53
 - circumcision of concealed penis, 53–54
 - classification, 62
 - factors affecting circumcision
 - complication rate, 50
 - factors relating
 - to circumciser, 54–55
 - to health status of baby, 50
 - method and technique of circumcision, 56
 - reporting of rate of circumcision complications, 56–62
- Concealed penis (CP), 50, 99, 108, 110, 184–187, 186f
 - circumcision of, 53–54
- Congenital inguinal hernia, 51–52
- Congenital primary lymphoedema, 131
- Corona of glans penis, 117–118
- Corporal injury, 156–157
 - circumcised child with marked lateral penile deviation, 161f
 - extensive penile haematoma after male circumcision, 161f
- Corpus spongiosum, 39
- CP. *See* Concealed penis (CP)
- CPS. *See* Canadian Paediatric Society (CPS)
- Cultural practices of circumcision, 13
- Cutaneous lymphangiectasia (CL), 128–130
- D**
- Dartos fascia, 39, 65–66
- Decircumcision. *See* Preputial reconstruction
- Deep system, 130
- Delayed type hypersensitivity, 42
- Denuded glandular surface, 101–102
- Dermal analgesia, 42
- Diarrhoea, 82
- Difficult micturition, 114–116, 119f
- Dindo classification, 3
- Diphtheria, 73
- Dissection technique for male circumcision, 32, 33f
- Dorsal arteries, 67
- Dorsal nerve, 41
- Dorsal penile nerve, 41
- Dorsal penile nerve block (DPNB), 41, 42f–43f
- Dorsoventral slit technique, 25
- Double circular incision. *See* Sleeve resection
- Double-blinded randomized controlled trial, 44
- DPNB. *See* Dorsal penile nerve block (DPNB)
- Dual tension restorer (DTR), 181, 182f
- E**
- EF. *See* Erectile function (EF)
- Emissary veins, 67
- EMLA. *See* Eutectic mixture of local anaesthetics (EMLA)
- Entrapped penis, 99
- Epidemiologic study design, 62
- Epispadias, 50, 53f
- Erectile function (EF), 173
- Eutectic mixture of local anaesthetics (EMLA), 41
- Excessive penile skin loss, 145–146
 - complete skin loss around penis, 148f
 - dorsal skin burning from using thermal cauterization, 149f
 - extensive fibrosis and contracture following skin loss, 147f
 - local skin flaps, 150f
 - transverse scrotal flap, 150f
 - ventral skin loss after guillotine male circumcision, 146f
- F**
- Female circumcision, 11. *See also* Male circumcision (MC)
- Female genital mutilation (FGM). *See* Female circumcision
- Fistula complications
 - clinical manifestations of, 154–155
 - management, 155
- Foreskin regeneration, 181
- Foreskin restoration. *See* Preputial reconstruction
- Fournier gangrene, 74–75, 77f, 162, 171–173
- Freehand circumcision, 25
- Frenular bleeding, 68
- Frenular preservation during dissection method of circumcision, 33, 35f
- Frenulum, 137–138
 - intact, 138f
 - stretched frenulum with intact prepuce, 139f
- Freudian psychoanalytic theory, 1
- Fungal or candida balanitis, 87f, 88
- G**
- Gastroenteritis, 82
- Glans injury, 146–147
 - glandular disfigurement after, 153f
 - late results of skin grafting, 153f
- Glans injury (*Continued*)
 - with loss of glandular urethra, 151f
 - management, 148–149
 - traumatic glandular hypospadias secondary to, 152f
- Glans penis, 49, 81, 111, 141, 142f
 - injury, 71f
- Glanular adhesions, 53–54
- Gomco clamp, 25–26, 27f
- Guillotine circumcision, 33–34.
 - See also* Neonatal circumcision
 - thermal cutting for, 32f
- H**
- Haemorrhagic shock, 65
- HBO. *See* Hyperbaric oxygen (HBO)
- HBOT. *See* Hyperbaric oxygen therapy (HBOT)
- Hemorrhagic and infectious complications, 50
- Heterosexual men, 19
- HIV. *See* Human immunodeficiency virus (HIV)
- HIV/AIDS. *See* Human immunodeficiency virus/acquired immune deficiency syndrome (HIV/AIDS)
- Hospital-based mass circumcision exercise, 55
- HPV, 19–20
- HPV. *See* Human papilloma virus (HPV)
- Human immunodeficiency virus (HIV), 17–18
 - circumcision and prevention, 19
- Human immunodeficiency virus/acquired immune deficiency syndrome (HIV/AIDS), 12–13, 21–22
- Human papilloma virus (HPV), 18, 21
- Hyalinosis, 90
- Hyperbaric oxygen (HBO), 172–173
- Hyperbaric oxygen therapy (HBOT), 171–172
 - hyperbaric chamber, 172f
 - hyperbaric oxygen cabinet for neonates and infants, 174f
 - infant with post-male circumcision ischaemia, 173f
 - post-male circumcision ischaemic injury, 174f
- Hypospadias, 50–51, 52f, 54f
 - PR in hypospadias surgery, 183
- I**
- Iatrogenic hypospadias, 149–154
- Ideal time for male circumcision, 3–4
- Immunocompromised, 50
- Incomplete circumcision, 99, 105–110, 115f
 - management, 109–110

Infantile penis, 105–107
 Infectious complications of
 circumcision, 73
 bacterial or pyogenic balanitis,
 84
 clinical manifestation, 80
 infected granuloma at dorsum of
 circumcision scar, 85f
 extensive skin loss from penile shaft,
 76f
 forcible preputial retraction in
 neonate, 74f
 fungal or candida balanitis, 88
 incidence, 73
 meatal stenosis, 95–97
 meatal ulcers, 93–94
 pathology, 73–75
 post-circumcision
 balanitis xerotica obliterans,
 89–90
 penile granuloma,
 76–77
 post-male circumcision
 balanitis, 81–84
 meatitis, 91–93
 post-MC granuloma, 78
 prevention, 75–76
 pyogenic infection, secondary to
 extensive skin removal, 75f
 treatment, 76, 80–81, 90–91
 of balanitis, 88–89
 silver nitrate stick cauterization,
 86f
 wide area of subcoronal
 granulation, 86f
 Innervation
 autonomic, 39
 somatic, 39–41
 Intact foreskin, 18
 Intact penis, 135–136
 Internal pudendal artery, 39
 Intraoperative bleeding,
 68–69
 Ischaemia, 74, 77f
 Isolated penile lymphoedema
 management, 132

K
 Keloid formation, 120–124, 123f
 Khitan, 3
 Kidney inflammation, 18

L
 Laser circumcision, 34–35, 37f
 Lateral preputioplasty, 182–183
 Local anaesthesia
 DPNB, 41
 subcutaneous ring block, 41–42
 Lymphangiectasia, 131
 Lymphangioplasty, 132
 Lymphatic vessels of superficial
 dermal plexus, 130
 Lymphoedema, 90, 128, 131, 183
 praecox, 131

M
 Magnitude of bleeding complication,
 68
 Maizels, 110
 Major complication, 3
 Male circumcision (MC), 1, 3–4, 17,
 19, 25, 41, 49, 65, 73, 99, 145,
 172–173. *See also* Circumcision;
 Guillotine circumcision; Neonatal
 circumcision
 anaesthesia
 and analgesia for MC, 44
 general, 41
 local, 41–42
 regional, 41
 topical anaesthesia, 42
 Ancient Egyptian male circumcision
 at adolescence, 6f
 appropriate time of performing, 4–9
 autonomic innervation, 39
 complications
 HBOT role, 171–175
 prevention, 177–178
 in contemporary world, 12–14
 and effect on sexual behaviour, 20
 future, 14
 global map of male circumcision
 prevalence by country, 1f
 high loose male circumcision with
 excess inner prepuce, 113f
 historical and religious background
 to, 11–12
 low loose, 114f
 male newborn with bilateral femur
 fractures, 2f
 nervous supply of penis and prepuce,
 39
 and prevention of human
 immunodeficiency virus infection,
 19
 relevant anatomy, 39
 and risk
 of penile cancer, 19
 of prostate cancer, 19–20
 small baby circumcised using razor in
 Africa, 27f
 somatic innervation, 39–41
 spectrum of post-MC complications,
 2
 stapler, 34, 36f
 tools, 26f
 and ulcerative sexually transmitted
 infections, 19
 Manual for Male Circumcision under
 Local Anaesthesia, 25
 MC. *See* Male circumcision (MC)
 Meatal injury, 149, 154f
 Meatal stenosis, 95–97
 discovered late after male
 circumcision, 96f
 marked meatal stricture, 96f
 post-male circumcision, 97f
 Meatal ulcers, 93–94
 large post-circumcision, 94f

Meatitis
 with erythema and vesication, 95f
 post-male circumcision,
 91–93
 Medical complication, 3
 Medical cyanoacrylate, 124–125
 Megameatus intact prepuce (MIP),
 154
 Megameatus intact prepuce, 58f
 Men sex with men (MSM), 19
 Methaemoglobinemia, 42
 Meticulous attention, 69
 Meticulous haemostasis,
 124–125
 Microphallus, 146
 Microposthia, 51
 Minor complication, 3
 MIP. *See* Megameatus intact prepuce
 (MIP)
 Mogen clamp, 25–29, 28f
 Mohel, 13, 26f, 137
 Monopolar cautery technique, 32
 MSM. *See* Men sex with men (MSM)

N
 Nafcillin, 76
 Napkin dermatitis, 4, 7f, 91
 National Organization of Restoring
 Men (NORM), 180
 Neodymium:yttrium-aluminum-
 garnet laser contact technique (Nd:
 YAG laser contact technique),
 34–35
 Neonatal circumcision, 4, 5f, 7f–8f,
 17, 22, 50, 178. *See also* Guillotine
 circumcision
 and anaesthesia, 8
 and coagulation status, 8
 and parents' rights to consent for
 procedure, 8–9
 and prematurity, 8
 rates, 1
 Nervous supply of penis and prepuce,
 39
 Non-therapeutic circumcision of male
 minors, 18–19
 Nonaesthetic circumcision scarring
 complications, 99–100
 incomplete circumcision,
 105–110
 keloid formation, 120–124
 paraphimosis, 117–120
 penile adhesions, 101–102
 post-circumcision penile
 lymphoedema, 128–132
 post-male circumcision
 concealed penis, 110–112
 phimosis, 112–117
 smegma collection, 125–126
 skin bridges, 103–105
 untidy circumcision, 100–101
 Nonsurgical foreskin restoration, 181
 Nonsurgical restoration method,
 180–181

- Nonsurgical tissue expansion
methods, 181
- NORM. *See* National Organization of Restoring Men (NORM)
- O**
- Obesity, 50, 51f
- Octyl cyanoacrylate, 33
- Oral sucrose, 44
- Organogenesis and BioSurface Technology, 14
- P**
- Paraphimosis, 117–120, 121f–122f
incidence, 118–119
management, 119–120
sequelae, 119
- Patient and Observer Scar Assessment Scale (POSAS), 100
- Pelvic plexus, 39
- Penile adhesions, 50, 101–102, 107f–108f, 139
circumcision scar and glans, 106f
predisposing factors, 101–102
- Penile amputation, 166–169
ablation penis with marked urethral stricture, 167f
management, 168–169
multiple bladder stone formation secondary to urine retention, 168f
severe urethral stricture pursue complete penile loss, 167f
- Penile anomalies, 54
- Penile arteries, 66f
- Penile cancer, 18, 21
epidemiology and risk factors, 21
involving prepuce, 22f
relationship between circumcision and, 21–22
risk of, 19
- Penile entrapment by circumcision scar, 112
- Penile granuloma, post-circumcision, 76–77
- Penile inflammation, 114–116
- Penile injuries, 145
- Penile irritation and inflammation, 21
- Penile ischaemia, 163–164, 163f
combined ischaemia and secondary penile infection, 164f
glandular ischaemia, 165f
management, 164–166
severe penile gangrene, 165f
treatment with pentoxifylline and hyperbaric oxygen, 166f
- Penile length (PL), 187
- Penile rotation, 50, 56f, 183–184, 185f
- Penile tourniquet syndrome, 152–154
- Penile visibility index (PVI), 54, 187
- Penis, 39, 40f, 49
blood supply of, 65–68, 66f
nervous supply of prepuce and, 39
- Penis (*Continued*)
nervous system, 40f
venous drainage, 67f
- Penoscrotal transposition, 50
- Penoscrotal webbing, 50, 55f
- Pentoxifylline, 148
- Perioperative factor replacement, 65
- Phalloplasty techniques, 168–169
- Phimosis, 17, 19, 117–118
risk, 22
- PL. *See* Penile length (PL)
- Plastibell circumcision, 74
- Plastibell clamp, 25, 28f, 29
- Plastibell method, 73
- Plastibell technique, 50, 56
- POSAS. *See* Patient and Observer Scar Assessment Scale (POSAS)
- Post-circumcision
balanitis xerotica obliterans, 89–90
cicatricial phimosis, 118f
infectious large ulcer over glans and coronal sulcus, 83f
penile granuloma, 76–77
candida infection of circumcision wound, 81f
infection following bleeding and heavy stitching, 79f
post-male circumcision infection results, 82f
Pseudomonas aeruginosa infection, 80f
subcoronal infection and necrosis, 78f
- penile lymphoedema, 128–132, 129f, 131f
cutaneous lymphangiectasia, 130f
diagnosis, 130–131
differential diagnosis, 131
pathophysiology, 130
treatment, 132
urethral injury, 149–154
- Post-male circumcision (Post-MC)
aesthetic complications, 99
balanitis, 81–84, 87f
bleeding, 68–69
intraoperative bleeding, 68–69
postoperative bleeding, 69
preoperative bleeding, 68
concealed penis, 110–112
complete, 111, 116f
partial, 111–112, 117f
granuloma, 78
large granuloma in ventral penile surface, 84f
small granuloma in coronal sulcus, 83f
small stitch and smegma granulomas, 85f
lymphoedema, 131
meatitis, 91–93
meatitis secondary to male circumcision, 91f
- Post-male circumcision (Post-MC) (*Continued*)
napkin dermatitis with involvement of urinary meatus, 90f
pyogenic meatitis complicating meatal and glandular injury, 92f
severe meatitis, 93f
Streptococcus pyogenes meatitis, 92f
penile injuries
clinical manifestations of fistula complications, 154–155
corporal injury, 156–157
excessive penile skin loss, 145–146
glans injury, 146–147
meatal injury, 149
penile amputation, 166–169
penile ischaemia, 163–164
post-circumcision urethral injury, 149–154
vascular injuries and ischaemia, 162–163
penile ischaemia, 172–173
phimosis (Post-MC phimosis), 112–117
treatment, 116–117
smegma collection, 125–126
suture marks, 124
- Posthioplastice. *See* Preputial reconstruction
- Posthioplasty. *See* Preputial reconstruction
- Postoperative bleeding, 69, 71f
- PR. *See* Preputial reconstruction (PR)
- Preoperative bleeding, 68
bleeding necessitates hospital admission and urinary catheter insertion, 72f
dorsal haematoma at site of local anaesthetic injection, 69f
- Preoperative factor replacement, 65
- Prepex device, 30–32, 31f
- Prepuce, blood supply to, 67, 68f
- Preputial cutting, 128
- Preputial oedema, 183
- Preputial reconstruction (PR), 180–183
marked preputial lymphoedema after, 185f
nonsurgical restoration, 180–181
preputial reconstruction in hypospadias surgery, 183
surgical restoration, 181–183
- Preputioplasty, 181–183
- Primary phimosis, 116
- Procedural risks, 18
- Prostate cancer, risk of, 19–20
- Pseudomonas aeruginosa* infection, 74
- Pudendal artery, 65–66
- Pudendal nerves, 41
- PVI. *See* Penile visibility index (PVI)
- Pyogenic balanitis, 84
- Pyogenic granuloma, 78
- Pyogenic penile infection, 74

- R**
- Randomized controlled trials (RCTs), 17
 - RB. *See* Ring block (RB)
 - RBCs. *See* Red blood cells (RBCs)
 - RCTs. *See* Randomized controlled trials (RCTs)
 - Reconstructive surgery for
 - circumcision complications
 - CP, 184–187
 - penile rotation, 183–184
 - preputial reconstruction, 180–183
 - principles of reconstruction of
 - complications after MC, 179–180
 - Red blood cells (RBCs), 171
 - Regional anaesthesia, 41
 - Religious circumcision, 13
 - Residual prepuce, 100
 - Ring block (RB), 41–42
 - Risk-benefit analysis, 18
 - Royal Dutch Medical Association (2010), 18–19

S

 - Saphenous vein, 67
 - Scalded skin syndrome, 73
 - Scalpel-free technique, 29
 - Scrotal implant flap, 181
 - Scrotal transposition, 57f
 - Secondary phimosis, 53–54, 108
 - Seizures, 42
 - Sensory receptors, 39–41
 - Sexual behaviour, effect on, 20
 - Sexually transmitted infections (STIs), 18
 - Shaft haematoma, 68, 70f
 - Shield, 25
 - Silver nitrate, 80, 86f
 - Single superficial dorsal vein, 66–67
 - Skin bridges, 103–105, 112f
 - incidence, 103
 - surgically excised skin bridges, and
 - fine stitching, 113f
 - treatment, 105
 - ventral skin bridge in penile curvature
 - during erection, 109f
 - wide area of skin creeping over glans, 111f
 - Skin bridges, 139, 140f
 - Skin expansion, 180–181
 - Sleeve resection, 32–33, 34f
 - Sleeve technique, 25, 29f, 56
 - Smart Klamp, 25–26, 29–30, 30f–31f
 - Smegma, 103
 - collection with dirt in circumcised
 - boy, 115f
 - cyst, 110f, 126, 127f–129f
 - granuloma, 78
 - Smegma (*Continued*)
 - post-male circumcision smegma
 - collection, 125–126
 - Solehring, 30
 - Somatic innervation, 39–41
 - Spitting sutures. *See* Post-MC suture marks
 - STIs. *See* Sexually transmitted infections (STIs)
 - Streptococcus pyogenes*, 93
 - meatitis, 92f
 - Subcutaneous connective tissue, 65–66
 - Subcutaneous ring block, 41–42, 44f–45f
 - Subcuticular suturing, 124–125
 - Subpreputial debris, 114–116
 - Superficial
 - penile fascia, 39
 - perineal Colles fascia, 65–66
 - system, 130
 - ulceration, 93
 - veins, 66–67
 - Surgical restoration method, 181–183
 - foreskin regeneration, 181
 - PR in hypospadias surgery, 183
 - preputioplasty, 181–183
 - Suture granulomas, 78
 - Suture marks, 124–125
 - Suturing, 34–35
 - Sympathetic chain ganglia, 39
 - Symphysis pubis, 39
 - Syphilis, 18
 - Systemic infectious complications, 73

T

 - Tahera. *See* Al-Tohour
 - Tara Klamp, 25–26, 30
 - Thermal cutting, 32
 - for guillotine circumcision, 32f
 - Thermocautery-assisted technique, 32
 - Tissue necrosis, 74
 - Topical anaesthesia, 42
 - Torsion, 184
 - Traditional guillotine-type
 - circumcision, 107
 - Trapped penis, 110, 184
 - Tribal mark, 17
 - Triple-incision preputioplasty, 183, 184f
 - Tuberculosis, 73

U

 - Ugly circumcision scar. *See* Untidy circumcision
 - UHMS. *See* Undersea and Hyperbaric Medical Society (UHMS)

Ulcerative sexually transmitted infections, 19

Uncircumcised penis, 135–136

Uncircumcision. *See* Preputial reconstruction

Undersea and Hyperbaric Medical Society (UHMS), 171

Undescended testicle, 51–52

Untidy circumcision, 99–101

 - aesthetic regular scar, 100f
 - excess inner preputial layer, 103f
 - irregular post-male circumcision
 - wavy scar, 101f
 - multiple glandular injuries, 104f
 - prominent stitch marks, 104f
 - unequal scar with excess outer and inner preputial layers, 102f

Urethra, 89–90

Urethral injuries, 49

Urethral meatus, 93

Urethrocutaneous fistula, 149–154

 - coronal fistula after plastibell injury, 155f
 - minute fistula proximal to meatus
 - secondary, 156f
 - obvious fistula detected early after male circumcision, 160f
 - post-male circumcision abnormal
 - fistula, 158f
 - unreported case of dorsal fistula in neonate, 158f
 - visible hair coil over the coronal sulcus, 159f
 - wide penoscrotal fistula, 157f

Urinary meatus, 91–93

Urinary tract infection (UTI), 2, 17, 75, 112

US Centers for Disease Control and Prevention (CDC), 4

V

 - Vancomycin, 76
 - Vascular injuries and ischaemia, 162–163
 - Venous drainage, 66–67
 - Ventral curvature and chordee, 50

W

 - Webbed penis, 51, 110, 184
 - World Health Organization (WHO), 25

Z

 - Zhenxi rings, 30

This page intentionally left blank



TECHNOLOGY &
ENGINEERING /SCIENCE

ISBN 978-0-323-68127-8



9 780323 681278



ELSEVIER

elsevier.com/books-and-journals